

## Aggressive Cyst of The Jaw - A Case Report

Anuja Agarwal<sup>1</sup>, Amit Tyagi<sup>2</sup>, Nishant Kumar<sup>3</sup>, Anshuman Ahuja<sup>2</sup>

### Abstract

Multiple treatments for the keratocystic odontogenic tumor have been proposed and debated. The challenge lies in minimizing both the risk of recurrence and morbidity of an extensive resection. While the cyst is a benign neoplasm, its recurrence rate ranges from 17–56% with simple enucleation and 1-8.7% following the application of Carnoy's solution or decompression before enucleation. Finally, resection is uniformly reported to result in essentially no recurrences. The immediate reconstruction of mandibular defects after resection presents a challenge to operating surgeon for retention of the position of the soft tissues and the contour of the lower face. Reconstruction plate permits restoration of speech, mastication, swallowing, and facial contour. We report a case of Keratocystic odontogenic tumor in the mandible which was surgically excised followed by maintenance of anatomic contours of the mandible by reconstruction plate.

**Key words:** Keratocystic odontogenic tumor, mandible, resection, reconstruction plate

### INTRODUCTION

The keratocystic odontogenic tumor (KCOT), formerly known as the odontogenic keratocyst (OKC), received its new designation in order to better convey its neoplastic nature<sup>1</sup>. It is a benign developmental odontogenic tumor with many distinguishing clinical and histologic features. Among them are: a potential for locally destructive behavior, a relatively high recurrence rate, and designation as a consistent finding in the nevoid basal cell carcinoma syndrome, or Gorlin syndrome. Numerous treatment modalities ranging from decompression alone, to simple enucleation with or without curettage, to resection have been employed<sup>2</sup>. The human mandible is a horseshoe shaped

bone which defines the profile and appearance of the lower third of the face. Thus it contributes to facial contour, proper occlusion, mastication, airway support, deglutition and speech<sup>3</sup>. Discontinuity of the mandible is caused by trauma, infection or the extirpation of a tumor and results in cosmetic deformity, psychological impairment and functional disability. Reconstruction of complex three-dimensional composite bony and soft-tissue defects is a paramount for rehabilitation of vastly hindered form and function. In general, mandibular loss due to benign processes results in preservation of soft tissue. In contrast, mandibulectomy for carcinoma more frequently results in large bone and neighboring soft-tissues, muscles and nerve

**Corresponding Author :** Dr. Nishant Kumar, Department of Oral and Maxillofacial Surgery, ITS Dental College, Hospital and Research Centre 47, Knowledge Park - III, Greater Noida (U.P.) (M) - 8750118906 E mail - dmishantmaxfac@gmail.com, nishantkumarr@its.edu.in

<sup>1</sup> Prof. & HOD, Department of Oral and Maxillofacial Surgery, ITS Dental College, Hospital and Research Centre, 47, Knowledge Park - III, Greater Noida (U.P.)

<sup>2</sup> Reader, Department of Oral and Maxillofacial Surgery, ITS Dental College, Hospital and Research Centre, 47, Knowledge Park - III, Greater Noida (U.P.)

<sup>3</sup> Senior Lecturer, Department of Oral and Maxillofacial Surgery, ITS Dental College, Hospital and Research Centre, 47, Knowledge Park - III, Greater Noida (U.P.)

defects. The goals of mandible reconstruction are: establishment of mandible continuity, establishment of an osseousalveolar base, correction of adjacent soft tissue defects, and it has to provide sufficient durability and strength to allow resumption of daily activities. The internal fixation ranges from simple Kirschner wire or braided stain-less steel wire to more elaborate bone plate. These should be used only as temporary spacer as they will often loosen or fracture over time<sup>4,5</sup>

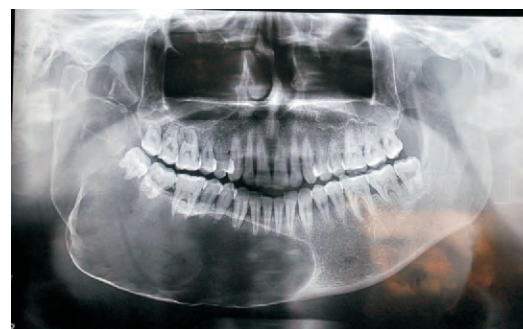**CASE REPORT**

A 42 year old patient reported to the department of Oral and Maxillofacial Surgery with complaint of swelling and pain in right lower back region of jaw since one month. The patient was apparently asymptomatic 2 years back when he noticed a swelling over the right lower back region of mouth which gradually increased in size. Patient was well oriented to time and place with no significant past medical and dental history. On clinical examination, an extraoral swelling of 4 cm x 3 cm was noticed extending mesio-laterally from commissure of lip to angle of the mandible and superior-inferiorly from 1cm below the tragus to 1 cm below the inferior border of the mandible. An obvious facial asymmetry of lower third of the face with obliteration of the right buccal vestibule was present (Fig 1).



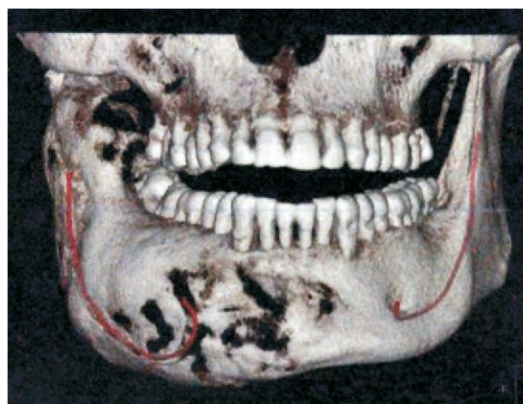
*Fig 1 – Swelling on lower third of face*

The intra-oral examination revealed expansion of buccal cortex. The Orthopantomogram (OPG) revealed a well defined unilocular radiolucency in the mandible extending from left canine region to the sigmoid notch on right side including the lower border (Fig 2).



*Fig 2 – OPG showing unilocular radiolucency on right side of mandible*

A Cone Beam Computed Tomogram (CBCT) showed multiple perforated regions in right side of mandible with expansion of bucco-lingual cortex (Fig 3).



*Fig 3 – CBCT with multiple perforated regions in right side of mandible with expansion of bucco-lingual cortex*

On histopathological examination, after an incisional biopsy a diagnosis of Keratocystic odontogenic tumor was made. The patient was operated for segmental resection of mandible followed by reconstruction with reconstruction plate (Orthomax recon 2.75 mm, Fig 4).

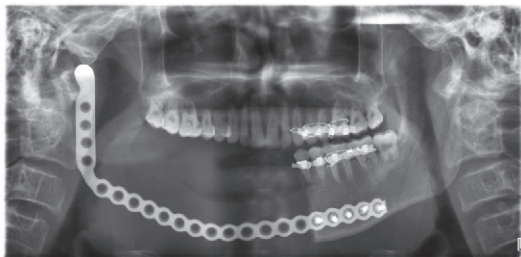

Fig 4 – Post surgical OPG with reconstruction plate

Post operative period was uneventful and after forty five days of follow up, the patient has no complaints.

#### DISCUSSION

The ablative surgery of maxillofacial region demands not just a radical removal of a tumor with primary or secondary reconstruction. Furthermore, the patient requires the full function and dental rehabilitation. To be a normal member of the society is sometimes more important for the patient than the success of radical tumorectomy and the possibility of the recurrences. There are some problems that occur from creating mandibular defects. Quinn et al<sup>6</sup> reported that the mandible plays a major role in airway protection and support of the tongue, lower dentition and the muscles of the floor of the mouth permitting mastication, articulation, deglutition and respiration. The planning for surgery is highlighted by the physical examination of the face and its contours. Imaging studies and digital data can also be used in the assessment as they could significantly contribute to mandibular reconstruction and implant stabilized occlusal rehabilitation. The treatment of these abnormalities requires the use of all applicable diagnostic aids<sup>7</sup>. For those purposes these imaging techniques are widely used: panoramic ortopantomography, cephalometric radiography (anterioposterior cephalogram, submental vertex views). With

imaging techniques available today, 3-D models can be created to determine the need for soft or hard tissue reconstruction and/or augmentation, rehearse the procedure, or even to serve as a template for the custom creation of facial implants<sup>8</sup>. Though there are many reconstructive options, from alloplastic bone substitutes to the autogenous bone grafts; the best suited reconstruction option for a particular patient is critical for the restorations of mandibular form and function. Autogenous bone grafting is probably the mainstay of mandibular reconstruction<sup>9</sup>. Sources of non-vascularized autogenous bone for grafting can be broadly divided into local and distant sites and their successful application to maxillofacial reconstructive surgery is well documented. If the defect requiring a graft is small, often local or intra-oral donor sites are sufficient. When a moderate to substantial amount of bone is required, the distant or extra-oral sites are usually employed<sup>10,11</sup>. Historically, free bone grafts were frequently used for mandibular reconstruction. Autogenous bone grafts from the calvarium, rib, ilium, tibia, fibula, scapula, and radius have been used<sup>12</sup>. Many different types of alloplastic materials have been used for mandibular reconstruction with varying rates of success. Synthetic materials such as methylmethacrylate, proplast and teflon which are nonbiodegradable and biocompatible have also been used, but success has been limited by breakdown of the overlying tissue with subsequent extrusion of the implant. Goode<sup>13</sup> reported the use of tobramycin-impregnated methacrylate in four patients with good results and noted that the methacrylate could be molded to fill any size defect and that the slow release of tobramycin decreased infection rates. With the



reconstruction plates mandibular function can be established by restoring the form, stiffness and load-bearing capacity of the mandible. Also, mandibular movement can be restored even by replacing mandibular condyle. Clinical observation in the present case demonstrated good function of the joint replacement with no adverse effect on the contralateral joint. Recent research into mandible reconstruction has focused on the use of tissue engineering approaches to repair bone defects, mostly in large animal models such as swine, goats, and primates. Scaffolds ranging from collagen sponges<sup>14</sup> to autologous autoclaved bone<sup>15</sup> have been used together with bone marrow-derived stromal cells and growth factors such as bone morphogenetic protein (BMP)-2 to facilitate osteogenic differentiation of implanted cells. BMP-2 has also been used clinically to aid in osseous regeneration of critical-sized mandibular defects with success<sup>16</sup>. Significantly, a tissue-engineered vascularized bone graft was used successfully to repair an extended mandibular defect in a man<sup>17</sup>. In conclusion, the reconstruction plate satisfies essential requirements of bone surgery in terms of functional stability, universal applicability and that reconstruction, can provide a significant reduction of morbidity in patients with osseous defects of the mandible.

**REFERENCES**

1. Barnes L, Eveson JW, Reichart P, Sidransky D, editors. World health organization classification of tumours: pathology and genetics of head and neck tumours. Lyon: IARC Press; 2005.
2. Giuliani M, Grossi G, Lajolo C, Bisceglia M, Herb K. Conservative management of a large odontogenic keratocyst: report of a case and review of the literature. *J Oral Maxillofac Surg.*2006;64:308–316
3. Papaxian Mr., Castille M.H., Campbell J.H., et al.:Analysis of reconstruction for anterior mandibular defects using AO plates. *J. Oral Maxillofac. Surg.*1991;49:1055
4. Assael L.: Mandibular reconstruction using cortical bone grafts placed with cancellous marrow on a reconstruction plate. *J. Oral Maxillofac. Surg.*1991;3:223
5. Austermann K., Becker R., Buning K. and Macbtens E.: Titanium implants as a temporary replacement of mandible. *J. Max. Fac. Surg.*1997;5:167
6. Quinn F., Sweeney Jr.K., Christopher C. and Rassekh H.: Mandibular reconstruction Dep. Otolaryngol. April 23, 1997.
7. Naitoh M, Katsumata A, Kubota Y, Arijji E. Assessment of three dimensional X-ray images: reconstruction from conventional tomograms, compact computerized tomography images, and multislice helical computerized tomography images. *J Oral Implantol* 2005; 31(5): 234–41.
8. Hallermann W, Olsen S, Bardyn T, Taghizadeh F, Banic A, Iizuka T. A new method for computer-aided operation planning for extensive mandibular reconstruction. *Plast Reconstr Surg* 2006; 117(7): 2431–7.
9. Genden E, Haughey BH: Mandibular reconstruction by vascularized free tissue transfer. *Am J Otolaryngol* 1996, 17:219-27.
10. Marx RE: Philosophy and particulars of autogenous bone grafting. *Oral Maxillofac Surg Clin North Am* 1993, 5:599-612.
11. Kainulainen VT, Sándor GKB, Clokie CML, Oikarinen KS: (a) Intraoral bone

- harvesting in oral and maxillofacial surgery. Suomen Hammaslääkärilehti 2002, 5:216-222
12. Urken ML, Buchbinder D: Chapter 86. Oromandibular Reconstruction. In Otolaryngology-Head and Neck Surgery. 3 edition. Edited by: Cummings CC. St Louis: Mosby Year Book, Inc; 1998:1654-1668
13. Goode RL, Reynolds BN. Tobramycin-Impregnated Methylmethacrylate for Mandible Reconstruction. Arch Otolaryngol Head Neck Surg 118:201 - 204, 1992.
14. Seto I, Marukawa E, Asahina I. Mandibular reconstruction using a combination graft of rhBMP-2 with bone marrow cells expanded in vitro. Plast Reconstr Surg 2006;117:902-908
15. von Wilmowsky C, Schwarz S, Kerl JM, et al. Reconstruction of a mandibular defect with autogenous, autoclaved bone grafts and tissue engineering: an in vivo pilot study. J Biomed Mater Res A 2010;93:1510-1518
16. Herford AS, Boyne PJ. Reconstruction of mandibular continuity defects with bone morphogenetic protein-2 (rhBMP-2). J Oral Maxillofac Surg 2008;66:616-624
17. Warnke PH, Springer IN, Wiltfang J, et al. Growth and transplantation of a custom vascularised bone graft in a man. Lancet 2004;364:766-770