

## Cone Beam CT Based Treatment Planning for Implant Retained Mandibular Overdenture using 3D Interactive Software

Praful Mehra<sup>1</sup>, Akshay Bhargava<sup>2</sup>, Sharad Gupta<sup>3</sup>, Sharad Vaidya<sup>4</sup>, Shikha Agarwal<sup>4</sup>

### Abstract

Implantology in present scenario has established a strong foothold in all aspects of prosthodontics be it removable or fixed. It has opened newer vistas of more predictable rehabilitation with greater patient comfort and improved quality of life. Implant retained mandibular overdenture is one such prosthetic modality. Cone Beam CT (CBCT)- the latest imaging modality with reduced dosage provides an accurate assessment of the anatomy of the implant site in three dimensions and aids in selecting the exact implant sites and sizes. This case report highlights how to interpret the CBCT data with the aid of 3D Interactive softwares for diagnosis & treatment planning of implant retained mandibular overdenture.

**Key words** : Implant retained mandibular overdenture, CBCT, 3D Interactive Software

### INTRODUCTION

In the last decade endosseous dental implants have become a popular choice in the rehabilitation of edentulous mandible. Edentulous persons, even with well adapted dentures have reduced capacity in various functions such as chewing ability, phonetics, tactile threshold and oral perception of hardness and thickness of objects. The major problems associated with mandibular denture i.e. retention and stability have been overcome by implants. The implant placement for such prosthesis is advocated in the interforaminal region i.e. the anterior mandible. Literature reports that implants placed in anterior mandible have a success rate of more than 95%<sup>1</sup>. Implant supported overdenture provides predictable results with improved stability, retention, function and patient satisfaction as compared to conventional dentures<sup>2</sup>.

For any successful implant procedure, an

accurate diagnosis with a comprehensive treatment planning is very crucial. Diagnostic imaging enables a clinician to appreciate the bone quality and quantity in totality. In 1972, Sir Godfrey Hounsfield presented a novel imaging technique referred to as Computerized Axial Transverse Scanning (CAT)<sup>3</sup>. CT is currently the only diagnostically justifiable imaging technique that allows for the conclusion of the structure and density of jaw bone<sup>2</sup>. The latest revolution in the field of imaging is Cone Beam CT (CBCT). This technology yields images with isotropic submillimeter spatial resolution and at the same time it has a very low radiation exposure<sup>4</sup>. The CBCT data when interpreted by 3D Interactive Software aids in accurate assessment of the implant site. It now becomes crucial to use this data and plan a rehabilitation of edentulous mandible.

**Corresponding Author** : Dr. Praful Mehra, Senior Lecturer, Department of Prosthodontics I.T.S Center for Dental Studies & Research, Delhi Meerut Road, Muradnagar, Ghaziabad, UP-201206. **E mail** : dr.prafulmehra@gmail.com (M) +91-9811311171

1 Senior Lecturer, Department of Prosthodontics, I.T.S Center for Dental Studies & Research, Delhi Meerut Road, Muradnagar, Ghaziabad, UP-201206.

2 Professor & HOD, Department of Prosthodontics, I.T.S Center for Dental Studies & Research, Delhi Meerut Road, Muradnagar, Ghaziabad, UP-201206.

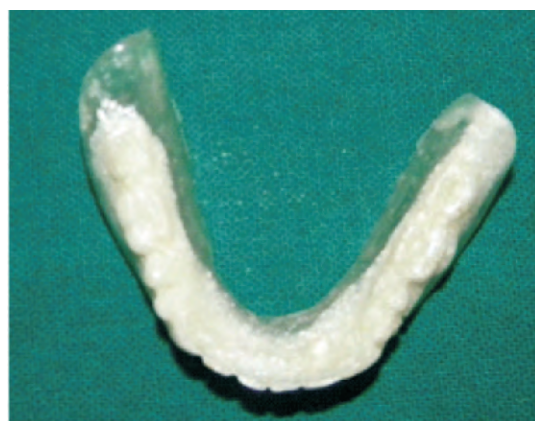3 Professor, Department of Prosthodontics, I.T.S Center for Dental Studies & Research, Delhi Meerut Road, Muradnagar, Ghaziabad, UP-201206.

4 Post Graduate Student, Department of Prosthodontics, I.T.S Center for Dental Studies & Research, Delhi Meerut Road, Muradnagar, Ghaziabad, UP-201206

**Case Report**

An edentulous male patient of 65years reported to the Department of Prosthodontics, Institute of Technology & Science- Center for Dental Studies & Research (I.T.S-CDSR), Muradnagar, Ghaziabad, UP with the chief complaint of difficulty in chewing food due to missing teeth. The patient was completely edentulous since one year.

Conventional complete dentures were fabricated for the patient. Radiographic guide was made by duplicating mandibular denture for the patient in which all the teeth were made from 30% Barium Sulphate powder and 70% Cold cure polymer (Trevalon, Dentsply)<sup>5</sup>.

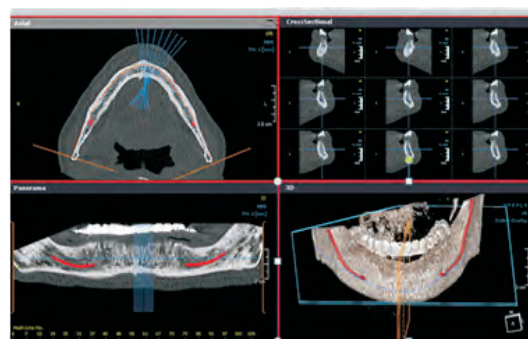


**Fig 1 : Radiographic Guide**

With the patient wearing this radiographic guide and maxillary denture a CBCT scan was conducted at 200micron resolution and medium Field of Vision (FOV) (9 X 15 cm) with Kodak 9500 CBCT scanner (Kodak Dental Systems, Carestream Health Inc. Rochester, NY) with a bite platform between the upper & lower arches. Exposure parameters used ranged from 85 – 90kV and 10-12 mA. Multi-planar image reconstruction and reformation was performed with interactive CBCT software (On Demand 3D™ Cyber-Med Inc. Seoul, South Korea). Pre-

implant bone assessment (i.e. bone height, width, angulation and subjective qualitative bone estimation) and virtual implant planning was performed using the pre-fabricated scan prosthesis as a reference.

Data Interpretation of CBCT Scan using 3D Interactive software was done. The CBCT data was viewed in four windows namely Axial view, Cross Sectional View, Panoramic View and 3D reconstructed View (Fig 2).



**Figure 2 : CBCT Data as viewed on 3D Interactive Software**

The slices from which the mental nerve exits was marked. Each slice measured 0.2mm in thickness and the interslice distance was prefixed to 1.5mm. The mental foraminas were indentified on Slice 46 and 75. The total interforaminal distance was calculated by the following formula:

$$\text{Interforaminal distance} = (\text{No of Slices} \times 0.2\text{mm}) + (\text{No of slices}-1) \times 1.5$$

$$\text{Total Slice Thickness} \quad \text{Total Interslice Distance} \\ \text{In this case it was } (18 \times 0.2) + (18-1 \times 1.5) = 29.1\text{mm}.$$

The anatomic centre of this span was identified which coincided with the radiographic midline of the denture as identified by mandibular central incisors of the radiographic guide. (Fig2)

The central slice was identified at 61. This was done to aid in the equidistant placement of

implants from the midline. A mandibular implant retained overdenture was planned for this case. Implant positions planned were

- Position A- Right mandibular first premolar region
- Position B- Right mandibular lateral incisor/ canine region
- Position D- Left mandibular lateral incisor/ canine region
- Position E- Left mandibular first premolar region

The positions decided for implants A and E were slice 50 and 71. These were exactly 6.4mm anterior to the mental foramina and the distal surface of the implants would have approximately 4mm of safe distance from the foramina.

The two anterior implants (B and D) were planned equidistantly anterior to the distal implants. The slices identified were 56 and 65. These center of the anterior implants would be 8.4mm from the midline and the distance between the midlines of anterior and posterior implant of each side would be 10mm. The average distance between the implants being 6mm helping in a favourable A-P spread.

Once the positions of implants was finalized the slices were viewed in cross sectional view and the height and width of the available bone was assessed using the measurement tools of the software.

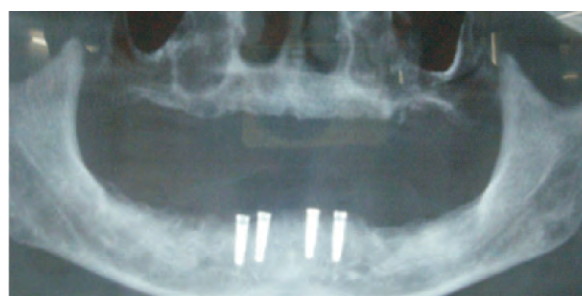
Virtual implant simulation was done and four Hi Tec two piece, self threaded, tapered implants of 3.3mm diameter and 10mm length were planned.

The mandibular denture was again duplicated in clear acrylic and based on the teeth positions of the denture and CBCT planning using the Radiographic guide as references the implant positions were identified and the positions

were drilled through the surgical guide.

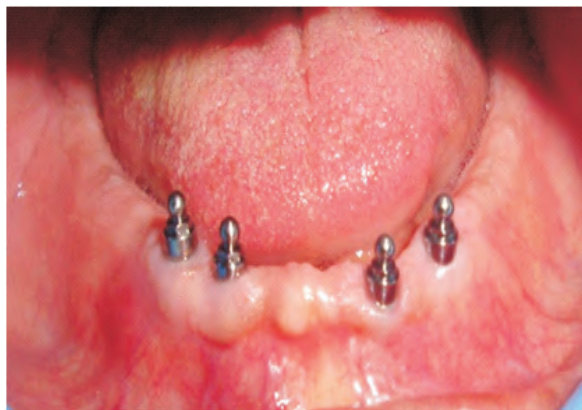Sequential osteotomy was done under copious irrigation in the desired positions and parallelism was checked using paralleling pins.

04 Hi Tec Implants (Two piece tapered self thread) were placed with a primary stability of 35 Ncm. Post operative OPG was taken. (Fig 3)



**Figure 3 : Post Implant Placement OPG**

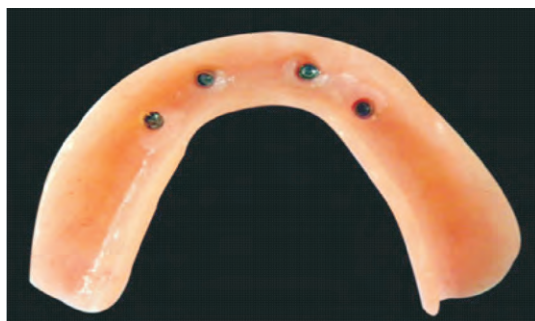A stage II surgery was performed after eight weeks and Dalla bona male attachments were torqued in at 25 Ncm (Fig 4) .



**Figure 4 :Dalla Bona Male Attachments**

Female parts of Dallabona attachments (Nylon ring and metal encapsulator) were picked intraorally in the denture using permanent intraoral reline material (UFI Gel Hard C Denture, VOCO, Germany) (Fig 5).





**Figure 5 :Intaglio Surface of Mandibular Prosthesis with Metal Encapsulator**

**DISCUSSION**

The emergence of CBCT has been a boon to the world of implantology. Studies have proven its accuracy and reliability<sup>6-9</sup>. Identification and measurement of the anterior loop of mental nerve is crucial when placing implants in the interforaminal region to avoid complication and injury to the neurovascular bundle plexus. A safe distance of 2mm for implants is recommended from the anterior loop of mental nerve.

Currently it is possible to use 3D interactive imaging softwares to allow computed tomography (CT) images to be used to virtually place dental implants and construct a precise guide splint and final prosthesis for delivery at the time of implant placement. However these modalities of guided surgeries add onto the cost of the procedure and may not be possible for all patients especially in the developing countries. Thus it becomes all the more pertinent to accurately interpret the CBCT data and transfer it to the cast using the indigenously made radiographic guide. In the case report described, the implant positions could be assessed and transferred aiding in a more predictable surgery and a favourable AP spread could be achieved. Further a safe distance of 4mm from the mental foramina was achieved on both sides.

**CONCLUSION**

Interactive computer imaging now allows the implant team to plan dental implant placement in virtual reality. This technology is a significant advancement over conventional computed tomography data alone. The simplicity of 3D softwares for treatment planning enables the clinician to plan a surgery more efficiently and predictably which ensures the success and longevity of the treatment.

**REFERENCES**

1. Shapurian T, Damoulis PD, Reiser GM, Griffin TJ, Rand WM. Quantitative evaluation of bone density using the Hounsfield index. *Int J Oral Maxillofac Implants* 2006;21:290-7
2. Adell R, Lekholm U, Branemark PI. A long term follow-up study of osseointegrated implants in the treatment of totally edentulous jaws. *Int J Oral Maxillofac Implants* 1990;5:347-59
3. Hounsfield GN. Computerized transverse axial scanning (tomography): 1. Description of systems. *Br J Radiol* 1973;46:1016-22
4. Garg AK. Dental implant imaging: TeraRecon's 3D Cone Beam Computed Tomography system. *Dent Impl Update* 2007;18:41-8
5. Basten CHJ, Kois JC. The use of barium sulfate for implant templates. *J Prosthet Dent* 1996;76:451-4
6. Piers CA, Bissada NF, Becker JJ, Kanawati A, Landers MA. Mandibular incisive canal: cone beam computed tomography. *Clin Implant Dent Relat Res* 2012;14:67-73
7. Hirsch JM, Branemark PI. Fixture stability and nerve function after

- transposition and lateralization of the inferior alveolar nerve and fixture installation. *Br J Oral Maxillofac Surg* 1995;33:276-81
8. Loubele M, Guerrero M E, Jacobs R, Suetens P, van Steenberghe D. A comparison of jaw dimensional and quality assessment of bone characteristics with cone beam CT, spiral topography and multi-slice spiral CT. *Int J Oral Maxillofac Implants* 2007;22:446-54
9. Lascala CA, Panella J, Marques MM. Analysis of accuracy of linear measurements obtained by cone beam computed tomography (CBCT- New Tom). *Dentomaxillofac Radiol* 2004;33:291-4