

Quantitative and qualitative analysis of T- lymphocytes in varying patterns of oral lichen planus - An immunohistochemical study

Juneja S¹, Srivastava D², Raina S³, Kumar K⁴, Shetty DC⁵, Rathore AS⁶

ABSTRACT

¹Senior Lecturer, ^{2,3}PG Student,
⁴Professor & Head, Department of
Oral Pathology, Subbaiah Institute of
Dental Sciences, Purle, Shimoga,
Karnataka.

⁵Professor & Head, ⁶Professor,
Department of Oral Pathology, I.T.S.
Dental College, Murad Nagar,
Ghaziabad, Uttar Pradesh,
PIN- 201206

Background: Oral lichen planus (OLP) is a T- cell mediated autoimmune disease in which the T cells trigger apoptosis of the basal cells of the oral epithelium. An early event involves keratinocyte antigen expression or unmasking of an antigen that may be a self-peptide. Later, the T- cells (mostly CD8 positive and some CD4 positive cells) migrate into the epithelium resulting in basal cell degeneration facilitated by a chemokine-mediated migration. These migrated CD8 positive cells are activated directly by antigen binding to major histocompatibility complex (MHC) - I on keratinocyte or through activated CD4 positive lymphocytes. Subsequent antigen presentation to CD4 positive T cells & interleukin (IL)-12 activates CD4+ T helper cells which activate CD8 positive T cells through receptor interaction, interferon- γ and IL-2. The activated CD8 positive T cells in turn kill the basal keratinocytes through tumor necrosis factor (TNF) - α or granzyme B activated apoptosis.

Aims and Objectives: To evaluate CD4 & CD8 positive T-lymphocytes qualitatively & quantitatively and their distribution in various clinical variants of oral lichen planus.

Methodology: The study comprised of a total 20 cases of OLP (atrophic-erosive and reticular variant) and 5 cases of normal oral mucosa which were histopathologically confirmed and then subjected to immunohistochemical staining with CD8 positive and CD4 positive antibodies using heat induced epitope retrieval method.

Results: The mean number of CD4 positive and CD8 positive cells were higher in atrophic-erosive variant of oral lichen planus (OLP) in comparison to the reticular variant.

Conclusion: Increased count of T lymphocytes in atrophic-erosive variant as compared to reticular OLP suggests their possible role in immunological mechanism in the pathogenesis of OLP and probably explains the reason for their higher malignant transformation rate as compared to other clinical forms of OLP.

Key words: Oral Lichen planus, Keratinocytes, Oral Mucosa, Premalignant, CD4 Positive T-Lymphocytes, CD8 Positive T-Lymphocytes

Received: 16-02-2015
Accepted: 26-03-2015

Introduction

Lichen planus (LP) is a chronic inflammatory mucocutaneous disorder that affects the skin, mucous membranes, nails, and scalp. Prevalence of oral lichen planus is about 0.5% to 2% with female to male ratios of approximately 2:1.¹

Oral lichen planus(OLP) is a T-cell mediated chronic inflammatory oral mucosal disease of unknown etiology.² OLP presents as white striations, papules, plaques, erythema, erosions or blisters affecting predominantly the buccal mucosa, tongue and gingivae.^{3,4} The World Health Organization (WHO) presently classifies OLP as oral potentially malignant disorder, particularly erosive and atrophic variants.⁵

The precise cause of Oral lichen planus (OLP) is not known. Few authors suggest it to be a T- cell mediated autoimmune disease; in which the T cells trigger apoptosis of the basal cells of the oral epithelium. Others suggest the cell mediated immunity to be involved in the pathogenesis of OLP.⁴

CD4 and CD8 T cell surface molecules play a role in T cell recognition and activation by binding to their respective class II and class I major histocompatibility complex (MHC) ligands on an antigen presenting cell (APC).⁶ Effector T cells are of three functional types that detect peptide antigens derived from different types of pathogen. Peptides from intracellular pathogens that multiply in the cytoplasm are carried to the cell surface by MHC class I molecules and presented to CD8 T cells. These differentiate into cytotoxic T cells that kill infected target cells.⁷

Peptide antigens from pathogens multiplying in intracellular vesicles, and those derived from ingested extracellular bacteria and toxins, are carried to the cell surface by MHC class II molecules and presented to CD4 T cells.⁷ It has been shown previously that cutaneous lichen planus is a T-cell mediated inflammatory disease with pathogenetic role of both CD8 positive cytotoxic T cells and CD4 positive helper T cells. There is a predominance of cytotoxic T cells in the dermal-epidermal infiltrate responsible for keratinocyte damage. Helper/inducer CD4 positive T cells are found in the perivascular dermal infiltrate, which may be assisting the cytotoxic cells in the keratinocyte damage.⁸ In oral lichen planus, an increased distribution and

Address for Correspondence:

Dr. Saurabh Juneja, Senior Lecturer, Department of Oral Pathology, I.T.S. Dental College, Murad Nagar, Ghaziabad, Uttar Pradesh, PIN- 201206
Email ID: drsaurabhjuneja@gmail.com

frequency of CD4 and CD8 positive T lymphocytes cells in the lamina propria predominantly in the sub-basal region has been shown.⁹

The present study was designed to assess CD4 & CD8 positive T- lymphocytes qualitatively & quantitatively and their distribution in various clinical forms of OLP and also to correlate the role of CD4 & CD8 positive T- lymphocytes in the pathogenesis and malignant potential of OLP.

MATERIAL AND METHODS

Sample Collection:

The study was conducted in the Department of Oral and Maxillofacial Pathology and Microbiology, I.T.S. Centre for Dental Studies and Research, Murad Nagar, Ghaziabad, Uttar Pradesh using the tissue specimens retrieved from the archives. 25 samples of formalin-fixed paraffin-embedded (FFPE) tissue specimens were selected from the archives of the department. A total of 10 cases of atrophic-erosive, 10 cases of reticular oral lichen planus and 5 cases of normal oral mucosa were selected. The selection criteria included OLP cases with history of occurrence of the lesion for 2-6 months (moderate disease duration). Patients with previous history of treatment for OLP were excluded from the study. All cases were reviewed and the diagnosis was confirmed according to the histopathological criteria defined by WHO (2003).

Immunohistochemistry procedure:

For immunohistochemical staining, 4µm FFPE tissue sections were deparaffinised and quenched in endogenous peroxidase enzyme for 10 min duration followed by immunostaining using the monoclonal mouse anti-human primary antibodies against CD4 & CD8 (Thermo Scientific). Heat induced epitope retrieval was done using antigen retrieval machine (Biogenex)

using citrate buffer. Antigen-antibody signal amplification was achieved by using an indirect enzyme labelled method by using a 3, 3'diaminobenzidine (DAB) as the chromogen. Sections of lymph node were used as positive controls.

Immunohistochemical evaluation:

The quantitative assessment was performed by selecting 5 representative fields at high magnification (40x) for each case. Photomicrographs of each field were captured and transferred onto the computer system for analysis using a digital grid using image analysis software (Olympus Magnus MLX series).1000 mononuclear immune cells in 5 HPF in basement membrane zone were counted for each case and the total number of cells and the number of positively stained cells were recorded.

The pattern, intensity and distribution of IHC staining of all the test and control sections were evaluated using a light microscope under various magnifications (up to 40x).The staining intensity was graded into four groups: 0- No staining, + (Weak, <10% cells stained), ++ (Moderate, 10-49% cells stained) and +++ (Strong, 50% or more cells stained).

RESULTS

CD4 positive T-lymphocytes and CD8 positive T-lymphocytes showed membranous or cytoplasmic staining in all the study cases. There was no difference in the distribution of the type of immune cells between reticular and atrophic-erosive OLP cases. However, CD4 positive cells were seen more predominantly in the subepithelial region while CD8 positive cells were diffusely distributed in the connective tissue in both reticular (Fig. 1,2) and atrophic-erosive variants of oral lichen planus (Fig. 3,4) study cases.

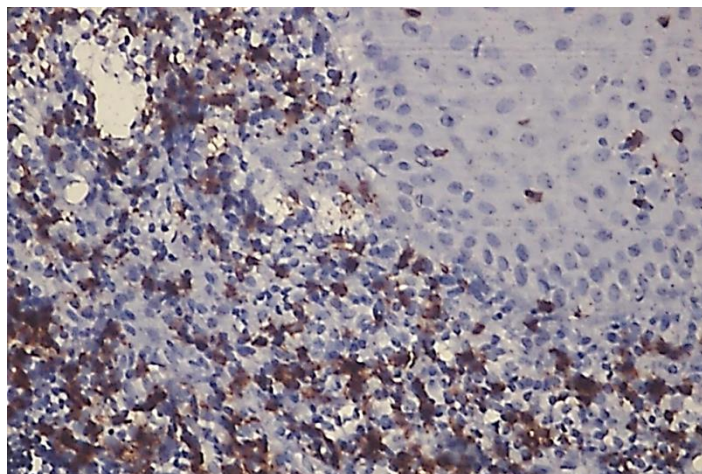


Fig. 1: Photomicrograph showing CD8 positive lymphocytes in the subepithelial region in reticular oral lichen planus (40x).

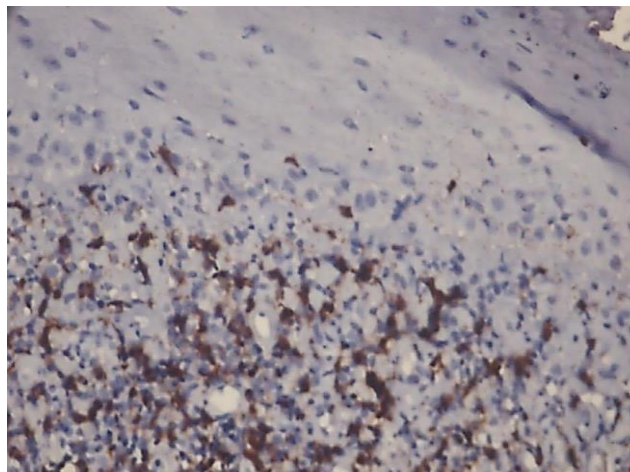


Fig. 2: Photomicrograph showing juxtaepithelial distribution of CD4 positive T- lymphocytes in reticular oral lichen planus (40x).

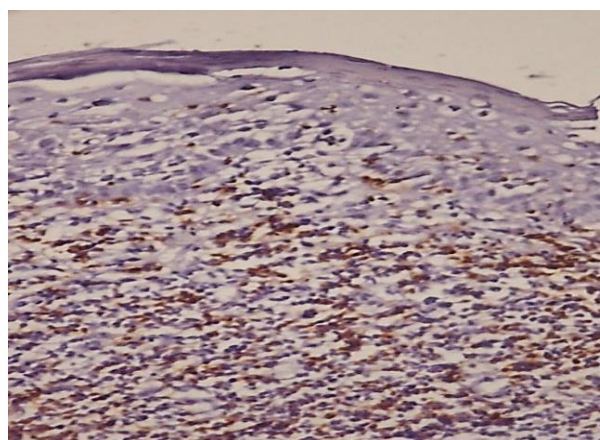


Fig. 3: Photomicrograph showing diffuse distribution of CD8 positive lymphocytes in atrophic-erosive oral lichen planus (40x).

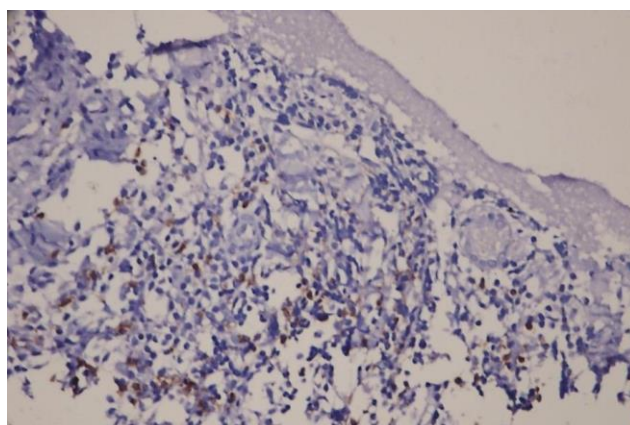


Fig. 4: Photo micrograph showing CD4 positive lymphocytes in atrophic-erosive oral lichen planus in the deeper connective tissue (10x).

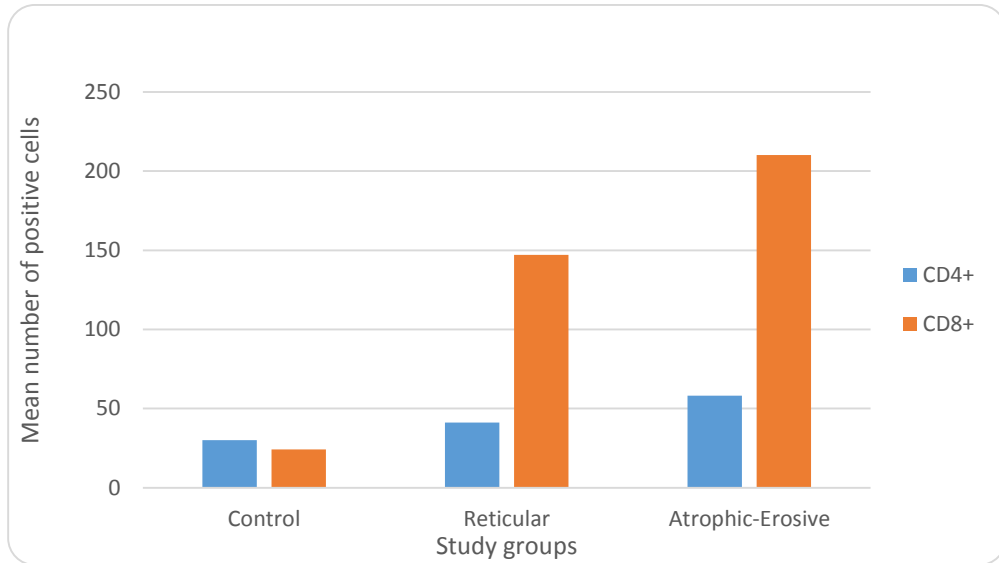
The mean number of CD4 positive cells were higher (58.20 ± 32.24) in atrophic-erosive in comparison to reticular lichen planus cases (41.20 ± 31.58) and control group (30 ± 6.78) (Graph1). The mean number of CD8 positive cells were also higher (210.20 ± 24.68) in atrophic-erosive in comparison to reticular lichen planus

cases (147.10 ± 29.37) and control group (24.20 ± 7.60) (Graph1). Both the observations were statistically insignificant ($p > 0.05$).

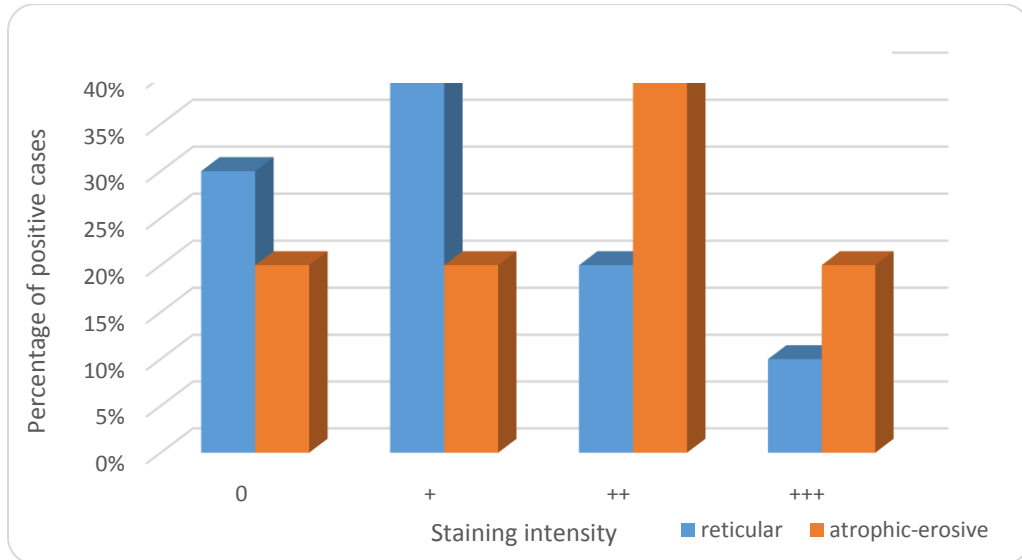
The staining intensity was assessed for CD4 positive and CD8 positive cells and it was observed that most of the study cases showed weak staining for CD4 positive cells in reticular

lichen planus group while predominantly moderate staining intensity was seen in atrophic lichen planus cases(Graph 2). CD8 positive

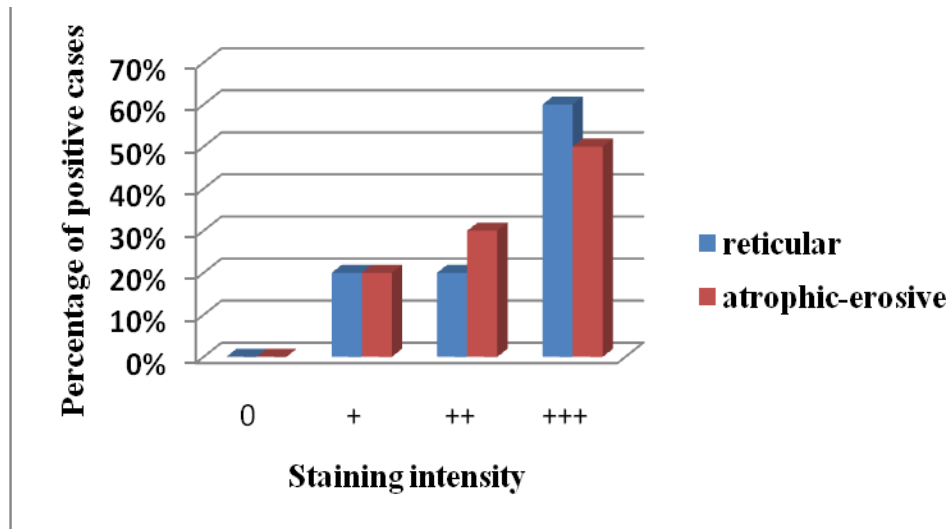
lymphocytes showed stronger staining intensity in reticular as well as in atrophic erosive lichen planus study groups (Graph 3).



Graph 1: Mean number of CD4 and CD8 positive T- lymphocytes in study groups



Graph 2: Staining Intensity of CD4 positive T- lymphocytes in the Study Groups



Graph 3: Staining Intensity of CD8 positive lymphocytes in the Study Groups

DISCUSSION

Oral lichen planus (OLP) is presently considered a chronic disease of unknown etiology and with a multifactorial pathogenesis. The reticular form of lichen planus, which is the most common type, is characterized by numerous interlacing white keratotic lines or striae that produce an annular or lacy pattern. The buccal mucosa is the site most commonly involved and demonstrates striae typically in a symmetric pattern bilaterally. Other sites involved may be tongue followed by gingiva and the lips. In the erosive form of lichen planus, the central irregular ulceration is usually covered by a fibrin plaque or pseudomembrane, often surrounded by fine radiant keratinized striae with a networked appearance. In the atrophic form, diffuse red lesions are exhibited and it may resemble the combination of two clinical forms, such as the presence of white striae characteristic of the reticular type surrounded by an erythematous area.^{10,11}

The modified WHO (2003) clinical criteria include bilateral presence of symmetrical lesions and white reticular lesions. The lesions may be atrophic, erosive, bullous or manifest in the form of plaque, appearing along with reticular lesions in a given area of the oral cavity. A classic case of lichen planus must satisfy the clinical criteria. Lesions that simulate a lichen planus but do not meet the modified WHO criteria are considered to be clinically compatible with lichen planus.¹²

Sinon et al confirmed the predominance of T lymphocytes over B lymphocytes, as has been previously shown by other studies (Hirota et al. 1990; Jungell et al. 1989; Walsh et al. 1990).¹³⁻¹⁶ The present study showed significantly higher number of T lymphocytes in OLP as compared to control cases. Also, in the present study, the number of CD8 positive cells were higher than CD4 positive cells in OLP cases

in all clinical variants (Graph 1). Dorrego et al¹⁷ and Khan A et al¹⁸ have also observed that higher number of CD8 positive T cells/ mm² compared to CD4 positive T cells. Contrary to this, some studies have shown a higher proportion of CD4 positive helper T lymphocytes compared to CD8 positive cells. Previous studies by Bhan AK et al¹⁹ have related cellular distribution with disease progression. In early lesions, there was an influx of CD4 positive helper T lymphocytes whereas in cases with longer duration there was a substantial increase in CD8 positive cytotoxic T cells which were associated with membrane disruption.^{16,20,21}

The present study also showed CD8 positive T-lymphocytes and CD4 positive T-lymphocytes constitute higher proportion of cellular infiltrate in atrophic-erosive lichen planus as compared to reticular lichen planus. Brant et al (2012)¹² found increased apoptosis of epithelial cells in basal and parabasal layer and number of lymphocytic infiltrate in the stroma of erosive lichen planus as compared to reticular form which contributes to decrease thickness of epithelium, facilitating erosion and ulceration corresponding to the aggressive clinical form in the former group. The author supported the above finding by stating that positive correlation between number of lymphocytes in inflammatory infiltrate and apoptosis in the epithelium in erosive OLP shows cause-effect association which seems to confirm that lymphocytes within the infiltrate are responsible for apoptosis of epithelial cells whereas minor symptoms, less inflammation and thereby less epithelial apoptosis in reticular OLP can be associated to the negative correlation between apoptosis in the inflammatory infiltrate and in the epithelium.²²

Karatsaidise et al. (2003) proposed that reduced epithelial thickness is not related to apoptosis but it may be contributed to abnormal or premature terminal differentiation of the keratinocytes which causes sloughing off keratinocytes from the epithelial surface. This pathological change in the epithelium (reduced epithelial thickness) possibly could be correlated to the production of different cytokines and growth factors (TNF- α , IFN- γ & IL-2) by inflammatory infiltrating cells mainly lymphocytic in nature.²³

Carewicz et al(2008)²⁴ showed that in initial lesions, corresponding with reticular forms of OLP, the predominant lymphocyte subset constitute CD4 positive T-lymphocytes, whereas in more advanced atrophic-erosive lesion the number of CD8 positive T-lymphocytes cells increases substantially as seen in the present study as well.

The staining intensity of CD8 positive and CD4 positive immune cells showed strong staining in OLP cases than controls in the present study. Among the OLP cases, atrophic-erosive group showed strong staining compared to reticular type and was found to be statistically significant for CD8 positive cells (Graph 3&4). Most authors support the idea that immune system allows proliferation and activation of T lymphocytes which are involved in OLP (Porter et al. 1997; Sugerman et al. 2002; Thornhill 2001; Walsh et al. 1990)^{16,20,25,26} Macrophage migration inhibitory factor(MIF) released from T-cells and macrophages, suppresses the transcriptional activity of the p53 tumor suppressor protein. This along with MMP-9 (released from T-cells) and keratinocyte TGF- β 1 may promote carcinogenesis in OLP. ²⁷

CONCLUSION

The number of CD4 positive and CD8 positive T lymphocytes were higher in OLP cases as compared to normal cases showing strong evidence of immunological mechanisms involved in the pathogenesis of OLP. Increase in CD4 and CD8 positive T lymphocytes in atrophic-erosive group in the present study explains the probable role of these subsets of immunological pathways in chronicity and malignant transformation rate of OLP.

REFERENCES:

1. Kenchappa M, Moger G, Puttalingaiah V D, Thippann C K. Erosive oral lichen planus with cutaneous involvement in a 7year old girl: A rare case report. J Indian Soc Pedod Prev Dent. 2013;31(3):197-200.
2. Sharma R, Sircar K, Singh S, and Rastogi V. Role of mast cells in pathogenesis of oral lichen planus. J Oral Maxillofac Pathol. 2011;15(3):267-271.
3. Sugerman PB, Savage NW. Oral lichen planus: causes, diagnosis and management. Aust Dent J. 2002 Dec;47(4):290-7.
4. Ismail SB, Kumar SK, Zain RB. Oral lichen planus and lichenoid reactions: etiopathogenesis,

diagnosis, management and malignant transformation. J Oral Sci. 2007 Jun;49(2):89-106.

5. Munde AD, Karle RR, Wankhede PK, Shaikh SS, Kulkurni M. Demographic and clinical profile of oral lichen planus: A retrospective study. Contemp Clin Dent. 2013 Apr;4(2):181-5.
6. Miceli MC, Parnes JR. The roles of CD4 and CD8 in T cell activation. Semin Immunol. 1991 May;3(3):133-41.
7. Janeway CA Jr, Travers P, Walport M, Shlomchik MJ. Immunobiology: The Immune System in Health and Disease.5th edition. New York: Garland Science; 2001.
8. Rana S, Gupta R, Singh S, Mohanty S, Gupta K, Kudesia M. Localization of T-cell subsets in cutaneous lichen planus: an insight into pathogenetic mechanism. Indian J Dermatol Venereol Leprol. 2010 Nov-Dec;76(6):707-9.
9. 9.Popovska M1, Grchevska L, Popovski V, Atanasovska-Stojanovska A, Minovska A, Belazelkoska Z, Radojkova-Nikolovska V, Mitik K, Strezovska S. T-cell subpopulations in lesions of oral lichen planus. Prilozi. 2013;34(2):144-50.
10. Regezi JA, Sciubba JJ, Jordan RCK. Oral pathology clinical pathological correlation.4th ed.Missouri:Saunders;2003
11. Canto AM, Müller H, Freitas RR, Santos PS. Oral lichen planus (OLP): clinical and complementary diagnosis. An Bras Dermatol. 2010 Sep-Oct;85(5):669-75.
12. Rad M, Hashemipoor MA, Mojtahedi A, Zarei MR, Chamani G, Kakoei S, Izadi N. Correlation between clinical and histopathologic diagnoses of oral lichen planus based on modified WHO diagnostic criteria. Oral Surg Oral Med Oral Pathol Oral RadiolEndod. 2009 Jun;107(6):796-800.
13. Sinon SH, Rich AM, Firth NA, Seymour GJ. Qualitative and Quantitative assessment of immune cells in oral mucosal lichen planus (OMLP).Sains Malaysiana. 2013;42(1):65-71.
14. Hirota J, Osaki T, Tatemoto Y.Immunohistochemical staining of infiltrates in oral lichen planus.Pathol Res Pract. 1990 Oct;186(5):625-32.
15. Jungell P, Konttinen YT, Nortamo P, Malmström M.Immunoelectron microscopic study of distribution of T cell subsets in oral lichen planus.Scand J Dent Res. 1989 Aug;97(4):361-7.
16. Walsh LJ, Ishii T, Savage NW, Gemmel E, Seymour GJ.Immunohistologic analysis of epithelial cell populations in oral lichen planus.J Oral Pathol Med. 1990 Apr;19(4):177-81.
17. Dorrego VM, Correnti M, Delgado R, Tapia FJ.Oral lichen planus: immunohistology of mucosal lesions.J Oral Pathol Med. 2002 Aug;31(7):410-4.
18. Khan A, Farah CS, Savage NW, Walsh LJ, Harbrow DJ, Sugerman PB.Th1 cytokines in oral lichen planus. J Oral Pathol Med. 2003 Feb;32(2):77-83.
19. Bhan AK, Harrist TJ, Murphy GF, Mihm MC Jr.T cell subsets and Langerhans cells in lichen planus: in situ characterization using monoclonal antibodies.Br J Dermatol. 1981 Dec;105(6):617-22.
20. Porter SR, Kirby A, Olsen I, Barrett W. Immunologic aspects of dermal and oral lichen planus: a review. Oral Surg Oral Med Oral Pathol Oral RadiolEndod. 1997 Mar;83(3):358-66.
21. Zhou XJ, Sugerman PB, Savage NW, Walsh LJ, Seymour GJ.Intra-epithelial CD8+ T cells and basement membrane disruption in oral lichen planus. J Oral Pathol Med. 2002 Jan;31(1):23-7.

22. Brant JM, Aguiar MC, Grandinetti HA, Rodrigues LV, Vasconcelos AC. A comparative study of apoptosis in reticular and erosive oral lichen planus. *Braz Dent J.* 2012;23(5):564-9.
23. Karatsaidis A, Schreurs O, Helgeland K, Axéll T, Schenck K. Erythematous and reticular forms of oral lichen planus and oral lichenoid reactions differ in pathological features related to disease activity. *J Oral Pathol Med.* 2003 May;32(5):275-81.
24. Charazinska-Carewicz K, Ganowicz E, Krol M, Gorska R. Assessment of the peripheral immunocompetent cells in patients with reticular and atrophic-erosive lichen planus. *Oral Surg Oral Med Oral Pathol Oral Radiol Endod.* 2008 Feb;105(2):202-5.
25. Sugerman PB, Savage NW, Walsh LJ, Zhao ZZ, Zhou XJ, Khan A, Seymour GJ, Bigby M. The pathogenesis of oral lichen planus. *Crit Rev Oral Biol Med.* 2002;13(4):350-65.
26. Thornhill MH. Immune mechanisms in oral lichen planus. *Acta Odontol Scand.* 2001 Jun;59(3):174-7.
27. Hudson JD, Shoaibi MA, Maestro R, Carnero A, Hannon GJ, Beach DH. A proinflammatory cytokine inhibits p53 tumor suppressor activity. *J Exp Med.* 1999 Nov 15;190(10):1375-82.

How to cite this Article: Juneja S, Srivastava D, Raina S, Kumar K, Shetty DC, Rathore AS. Quantitative and qualitative analysis of T- lymphocytes in varying patterns of oral lichen planus - An immunohistochemical study. *J Dent Specialities*,2015;3(1):29-35

Source of Support: NIL

Conflict of Interest: None Declared