

Eruption cyst due to supernumerary tooth - a chance occurrence

Nidhi Agarwal,¹ Dipanshu Kumar,² Samragini Banarjee,³ Aparna Singh.⁴

¹Professor and Head,

²Reader,

^{3,4}Postgraduate student,

Department of Pedodontics and Preventive Dentistry, Institute of Dental Studies and Technologies, Modinagar, Uttar Pradesh, INDIA

Address for Correspondence:

Dipanshu Kumar,

Department of Pedodontics and Preventive Dentistry, Institute of Dental Studies and Technologies, Modinagar, Uttar Pradesh, INDIA

E-mail: drdipanshu.kumar@gmail.com

Received: 03/01/2016

Accepted: 17/03/2016

ABSTRACT

Eruption cyst is a benign cyst associated with a primary or permanent tooth in its soft tissue phase after erupting through the bone. This case report documents a rare case in which the presence of supernumerary tooth hindered the normal eruption of permanent right maxillary central incisor subsequently the deficient space resulted in the formation of eruption cyst. The treatment included the extraction of supernumerary tooth followed by the surgical exposure of crown of the tooth associated with the eruption cyst. The present case report illustrates that the treatment of choice must be case specific with adequate analysis of clinical and radiographic findings and should be managed appropriately in order to minimize complications to the developing and erupting tooth.

Key Words: Eruption Cyst, Supernumerary Tooth, Odontogenic Cyst

INTRODUCTION


The eruption cyst (EC) is a benign, developmental, odontogenic cyst accompanying an erupting primary or permanent tooth and appears shortly before the appearance of these teeth in the oral cavity.¹ In the past, EC was considered a type of dentigerous cyst occurring in the soft tissues. Although there are a number of theories about their origin, both seem to arise from the separation of the epithelium from the enamel of the crown of the tooth due to an accumulation of fluid or blood in a dilated follicular space. The dentigerous cyst develops around the crown of an unerupted tooth lying in the bone, whereas the eruption cyst occurs when a tooth is impeded in its eruption within the soft tissues overlying the bone. According to World Health Organization (WHO) classification of epithelial cysts of the jaws, EC is considered as a separate clinical entity.² Development of the tooth is a continuous process with a number of physiologic growth processes and various morphologic stages interplay to achieve the tooth's final form and structure. Interference with the stage of initiation, a momentary event, may result in single or multiple missing teeth (hypodontia or oligodontia respectively) or supernumerary teeth.³ A supernumerary tooth is one that is additional to the normal series and

can be found in almost any region of the dental arch. It can be single or multiple, unilateral and bilateral, malformed morphologically or normal in size and shape, erupted or impacted. Most of the supernumerary teeth are asymptomatic, though its existence may cause pathological condition such as failure of eruption of the maxillary incisors, displacement or rotation of the permanent tooth, crowding, diastema and cyst formation.⁴

The majority of the time eruption cyst occurs as an isolated phenomenon⁵; however the presence of supernumerary tooth resulting in the formation of eruption cyst has never been reported in the dental literature. This report documents a rare case of supernumerary tooth which hindered the normal eruption of permanent right maxillary central incisor and due to the deficient space for eruption subsequently resulted in the formation of eruption cyst.

CASE REPORT

A 9 year old healthy male child reported to the Department of Pedodontics, Institute of Dental Studies and Technologies, Modinagar with the chief complaint of swelling on the gums in the upper front teeth region since 2 weeks. The patient had a noncontributory medical history. There was no history of any acute infection, trauma, drug or food allergy in the recent past. The swelling started appearing 2 weeks back over normal mucosa and is slowly increased to its present size causing mild discomfort and esthetic problems. Soft tissue examination showed the presence of single well demarcated dome shaped gingival swelling extending from labial to palatal gingival by crossing over alveolar ridge of 11. Clinically the gingival lesion appeared as bluish-black and measured approximately

Access this article online	
Quick Response Code:	Website: www.innovativepublication.com
	DOI: 10.5958/2393-9834.2016.00020.6

1.5 × 2 cm and was soft in consistency, fluctuant and mild tender on palpation. Examination of the oral cavity revealed that the child was in the mixed dentition stage and a conical shaped supernumerary tooth was found between swelling with respect to unerupted 11 and unerupted 12 (Fig. 1). The general physical examination of the child showed polydactyly in both the hands (Fig. 2). The intra oral periapical radiograph confirmed the presence of 11 in the stage of eruption and supernumerary teeth between unerupted 11 and 12 and there were no signs of bone involvement although a pericoronal shadow of soft tissue covering the crown of erupting 11 was seen (Fig. 3). It was clinically and radiographically diagnosed as eruption cyst with 11.

The clinical condition was explained to the parents and it was decided to extract the supernumerary tooth followed by the surgical intervention of the cyst under local anaesthesia. A blood investigation was carried out before the procedure and the consent for surgical procedure was obtained. The supernumerary tooth was extracted without any complications and surgical exposure was carried out by cutting a window leading to the exposure of the 11 (Fig. 4 and 5). Post operative instructions were given and the excised tissue specimen was sent for histopathological examination. The patient was reviewed after 1 week which revealed uneventful post operative healing and the tooth showed a normal eruption pattern (Fig. 6).

The histopathological examination showed an inner lining of stratified squamous nonkeratinized epithelium with an underlying connective tissue stroma. The cystic stroma was extremely cellular and showed a moderate chronic inflammatory cell infiltrate. Based on the histopathological findings, a final diagnosis of eruption cyst was made.

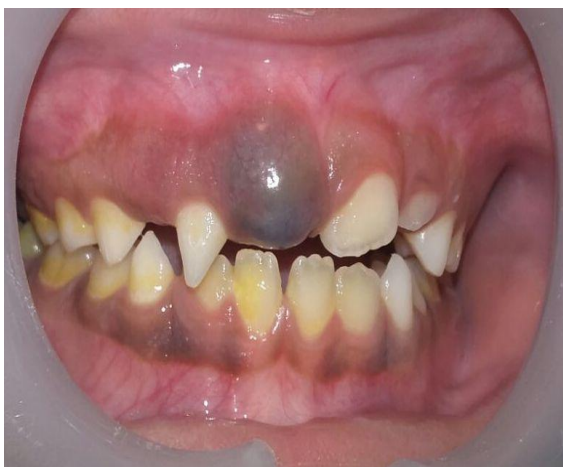

Fig. 1: Intraoral view showing gingival swelling and supernumerary tooth

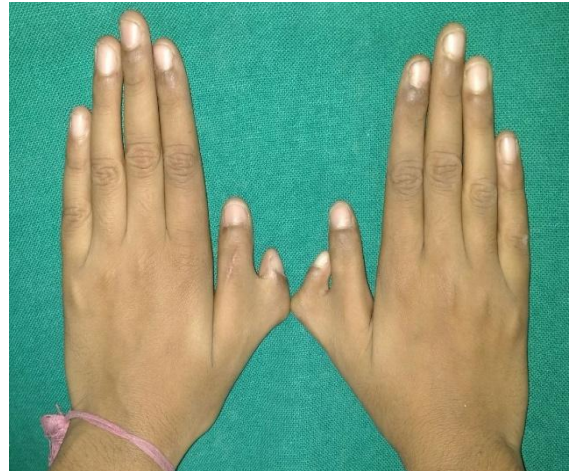

Fig. 2: Both the hands showing polydactyly

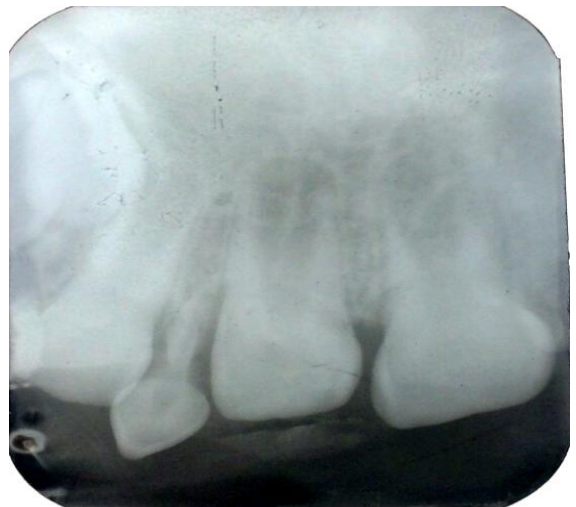

Fig. 3: Intraoral periapical radiograph showing pericoronal shadow of soft tissue covering the erupting tooth and supernumerary tooth

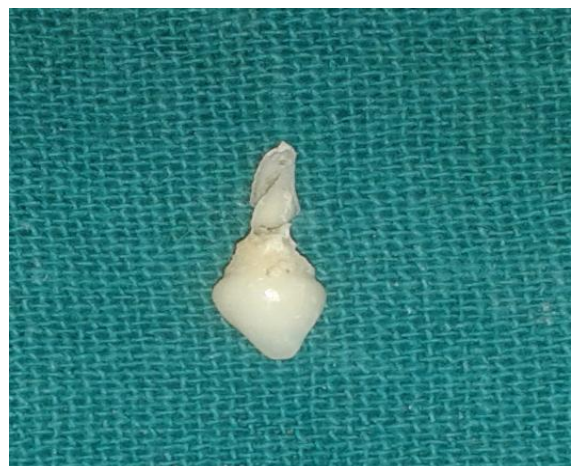

Fig. 4: Extracted supernumerary tooth

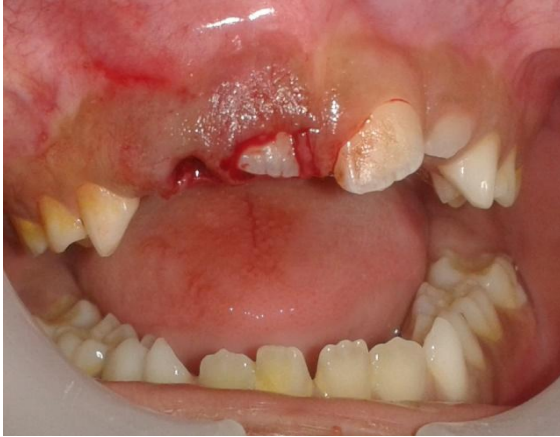

Fig. 5: Surgical exposure was carried out to expose the erupting 11

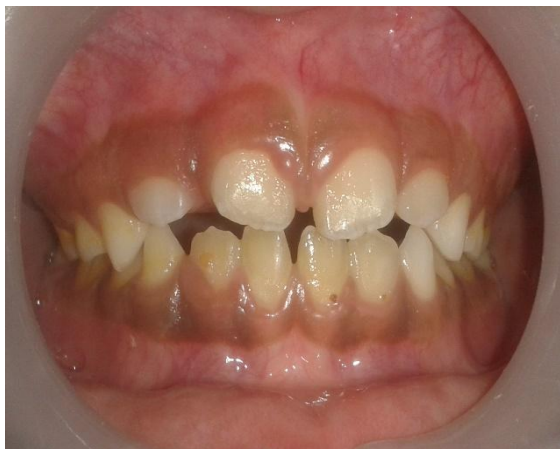

Fig. 6: Post-operative view showing the normal eruption of 11

DISCUSSION

Dental eruption is a process without any major events, but if something unusual happens during this period then it can be a stressful experience. It can be speculated that during the eruption process, the follicular space surrounding the tooth crown can be filled with tissular fluid, which produces a swelling in the alveolar ridge causing the formation of eruption cyst.⁶ Extensive review of the literature reveals a low prevalence of eruption cysts which might be due to the fact that most often dentist sees only symptomatic eruption cysts and the majority resolve unnoticed.^{1,7,8} Shear reported 0.8% frequency of occurrence rate for eruption cysts in his study of pathological specimens over a period of 32 years⁹, whereas Bodner found a prevalence rate of 22% among various maxillary cystic lesions in 69 children.⁸ Anderson¹ reported 54 cases over 16 years and Aguilo et al⁷ accounted for 36 cases in their retrospective study of 15 years.

EC usually appear in the first and second decade of life with mostly occurring in an age range of 6–9 years, a period coinciding with the eruption of permanent first molars and incisors.^{1,7,8,10} The general opinion is that

eruption cysts are most frequently seen in the teeth anterior to the permanent first molars. Anderson in a retrograde study on EC reported that it occurs more commonly in males than in females and more frequently on the right side than left¹ however, according to Pinkham no gender predilection is present.¹¹ Aguilo et al reported that 2.8% of EC occurred in the incisal and molar areas and the remaining 17.2% occurred in the canine-premolar areas⁷ while very few cases of EC have been reported to occur with natal and neonatal teeth.¹² EC is most frequently found in the permanent dentition which can be due to the fact that eruption cysts in the primary dentition are mainly dealt by paediatricians.¹

Clinically, the lesion appears as a circumscribed, fluctuant swelling in the mucosa of the alveolar ridge over the site of erupting tooth. It may be either the color of normal gingival or when surface trauma results in considerable amount of blood in the cystic fluid, the color can range from transparent, bluish, purple to blue-black in color. Usually, pain or tenderness on palpation only occurs when the eruption cyst has become infected.^{1,8,9} In spite of being a soft tissue lesion the radiographic examination is recommended to evaluate both the underlying tooth and bone. On radiographic examination, it is difficult to distinguish the cystic space of eruption cyst because both the cyst and tooth are directly in the soft tissue of the alveolar crest and no bone involvement is seen in contrast to dentigerous cyst in which a well-defined unilocular radiolucent area is observed in the form of a half-moon on the crown of a non-erupted tooth.¹ Histologically, this cyst presents the same microscopic features as the dentigerous cyst, with connective fibrous tissue covered with a fine layer of non-keratinized cellular epithelium.¹ Few of the conditions that could be considered in the differential diagnosis of the eruption cyst are haemangioma, neonatal alveolar lymphangioma, Bohns nodule, pyogenic granuloma, amalgam tattoo etc.⁷

The exact aetiology of occurrence of EC is not clear, however early caries, trauma, infection and the deficient space for eruption are implicated as possible causative factors.⁷ Brave and Bhatt¹³ proposed the presence of fibrous tissue as a factor possibly impeding tooth eruption, moreover other factors like early caries, chronic periapical inflammation or trauma in the primary teeth as well as a certain genetic predisposition, were ruled out in the present case by the patient's history. As a result, in the present case we believe that deficient space for the eruption of the permanent right maxillary central incisor due to the presence of supernumerary tooth was the reason for the development of the eruption cyst.

The majority of these cysts subsides spontaneously on their own and usually does not require any treatment, consequently postponing the treatment should be considered first.¹⁴ However in the present case the supernumerary tooth was impeding the favorable

eruption of the right maxillary central incisor and resulted in the formation of eruption cyst. Hence, it was decided to extract the supernumerary tooth and surgical intervention was carried out to expose the tooth crown. A careful monitoring of the size and appearance of the cyst is indicated and the local factors impeding the eruption of permanent tooth if present should be removed as soon as possible along with the necessary surgical intervention to facilitate tooth eruption.

CONCLUSION

The present case report illustrates that sometimes disturbances of the dental development may result in alarming appearances for the parents as well as health care providers. The treatment of choice must be case specific with adequate analysis of clinical and radiographic findings and should be managed appropriately in order to minimize complications to the developing and erupting tooth.

REFERENCES

1. Anderson RA. Eruption cyst: A retrograde study. *J Dent Child* 1990;57:124-27.
2. Bodner L, Goldstein J, Sarnat H. Eruption cysts: a clinical report of 24 new cases. *J Clin Pediatr Dent* 2004;28:183-86.
3. Hattab FN, Yassin OM and Rawashdeh MA. Supernumerary teeth: Report of three cases and review of the literature. *ASDC J Dent Child*, 1994;61:382-93.
4. Koch H, Schwartz S and Klausen B. Indications for surgical removal of supernumerary teeth in the premaxilla. *Oral Maxillofac Surg Int J*, 1986;15:273-81.
5. Nagaveni NB, Umashankara KV, Radhika NB, Maj Satisha TS. Eruption cyst: A literature review and four case reports. *Indian J Dent Res* 2011;22:148-51.
6. Hayes PA. hamartomas, eruption cyst, natal tooth and Epstein pearls in a newborn. *J Dent Child*, 2000;67:365-58.
7. Aguilo L, Cibrian R, Bagan JV, Gandia JL. Eruption cysts: retrospective clinical study of 36 cases. *J Dent Child* 1998;65:102-06.
8. Bodner L. Cystic lesions of the jaws in children. *Int J Pediatr Otorhinolaryngol* 2002;62:25-29.
9. Shear. *Cysts of the oral regions*. 3rd ed. Boston: Wright; 1996. p 99-102.
10. Seward M. Eruption cyst: an analysis of its clinical features. *J Oral Surg* 1973;31:31-35.
11. Pinkham JR, Casamassimo PS, Tighe DJ, Fields HW, Nowak AJ. *Pediatric dentistry: Infancy through adolescence*. 4th ed. St. Louis. Missouri: Saunders, An imprint of Elsevier: 2005.
12. Ricci HA, Parisotto TM, Giro EM, de Souza Costa CA, Hebling J. Eruption cysts in the neonate. *J Clin Pediatr Dent* 2008;32:243-46.
13. Brave VR, Bhatt AP. Case of the month. Eruption cyst. *J Indian Dent Assoc*. 1983;55: inside front cover.
14. Boj JR, Garcia-Godoy F. Multiple eruption cysts. Report of case. *J Dent Child* 2000;67:282-84.

How to cite this article: Agarwal N, Kumar D, Banarjee S, Singh A. Eruption cyst due to supernumerary tooth: A chance occurrence. *J Dent Specialities* 2016;4(1):99-102.

Source of Support: NIL

Conflict of Interest: All authors report no conflict of interest related to this study.