

Second premolar extraction improves the angulation of developing third molars better than first premolar extraction among subjects undergoing comprehensive orthodontic treatment

Cheshta Yadav,¹ Ashok Kumar Utreja,² Satinder Pal Singh,³ Ashok Kumar Jena.⁴

¹Ex-Junior Resident,

²Ex-Professor and Head,

³Professor,

Department of Orthodontics,

Post Graduate Institute of Medical Education & Research, Chandigarh, INDIA

⁴Assistant Professor,

Department of Dental Surgery,

All India Institute of Medical

Sciences, Odisha, INDIA

Address for Correspondence:

Ashok Kumar Jena,

Assistant Professor,

Department of Dental Surgery,

All India Institute of Medical

Sciences, Odisha, INDIA

E-mail: ashokjena@yahoo.co.in

Received: 10/01/2016

Accepted: 15/03/2016

ABSTRACT

Objective: To test the null hypothesis that premolar extraction had no favorable effect on the angulation of developing third molar among subjects undergoing comprehensive orthodontic treatment.

Materials and Methods: Pre- and post-treatment orthopantomograms of 73 subjects in the age range of 13-24 years were divided into three groups to evaluate the effect of premolar extraction on the improvement of developing third molar angulation. Group-I (n=26) included subjects in whom all first premolars were extracted, Group-II (n=20) included subjects in whom all second premolars were extracted and Group-III (n=27) included subjects in whom non-extraction orthodontic treatment was carried out for the correction of their malocclusion. Descriptive statistics, paired t-test were used for the statistical analysis. The P-value of 0.05 was considered as level of significant.

Results: The mean angulations of maxillary third molars were increased significantly following first and second premolars extraction treatment (P<0.01). The mean angulations of mandibular third molars were increased marginally following first premolars extraction treatment, however the mean angulations of the mandibular third molars were increased significantly following second premolars extraction treatment (P<0.05). The changes in the angulations of maxillary and mandibular third molars after non-extraction orthodontic treatment were very modest and statistically not-significant.

Conclusions: Extraction of first and second premolars had favorable effect on the angulation of developing third molars. The favorable changes were more following the second premolars extraction as compared to the all first premolars extraction.

Keywords: Premolar Extraction, Third Molar Angulation, Orthodontic Treatment.

INTRODUCTION

The development of third molars and their influence on the dental arches has long been of concern to the dental profession.¹ The developmental path of third molars in human beings is very irregular and the formation, calcification timing and the position and course of eruption show great variability. Frequently, third molars are impacted or congenitally missing.² The impact of third molar eruption on mandibular incisor crowding has been the objective of many studies.³⁻⁵ Causes for third molar impaction and predictions of third molar eruption have also been studied extensively.^{6,7} In contrast, the effect of orthodontic treatment on the developing third molars has not been subjected to much investigation. Although there are few studies in the literature evaluating the effect of premolar extraction on developing third molars but the


results of these studies were inconclusive.^{1,8-14} Thus the present study was designed to evaluate the effects of orthodontic treatment with first and second premolars extraction on the angulation of developing third molars.

MATERIALS AND METHODS

The study was approved by the Institute Review Board (IRB No- NK/758/MDS/8967-68). The pre-treatment and post-treatment orthopantomograms of 73 (M=33, F=40) patients in the age range of 13-24 years available in the record archive of the Unit of Orthodontics were selected for the study. The following inclusion and exclusion criteria were strictly followed while selecting the records of the subjects for the study.

Inclusion criteria:

1. Presence of good quality pre-treatment and post-treatment records like orthopantomograms and study models.
2. The details of the mechanotherapy with date were mentioned in the doctor's note sheet.
3. Class I molar relationship bilaterally.
4. Presence of third molar crowns at least in Nolla's¹⁵ stage 5 of tooth development (crown almost completed) at the time of beginning of orthodontic treatment.
5. Presence of third molar in the quadrant in which premolar extraction was done.

Access this article online	
Quick Response Code:	Website: www.innovativepublication.com
	DOI: 10.5958/2393-9834.2016.00009.7

6. Patients in whom extraction spaces had been fully closed.

Exclusion criteria:

1. Missing teeth other than first and second premolars.
2. Patients with any known syndrome.
3. Patients in whom Class II or Class III elastics were used for the correction of molar relationship following closure of extraction spaces.

The presence of Class I molar relationship was evaluated from the study models. All pre-treatment orthopantomograms were recorded within 1-month before the start of orthodontic treatment and all the post-treatment orthopantomograms were recorded 1-week after the completion of comprehensive orthodontic treatment. All the orthopantomograms were recorded on the same panoramic unit (Kodak 8000C Digital Panoramic and Cephalometric System) with similar exposure parameters (73 kV, 12 mA and 13.93s). The duration of orthodontic treatment in all the subjects ranged from 18-36 months (Mean duration, 27.51±6.17 months). The subjects (n=73) were divided into three groups. Group-I (n=26; M=12, F=14) included all the subjects in whom all first premolars were extracted for the orthodontic treatment, Group-II (n=20; M=09, F=11) included subjects in whom all second premolars were extracted for the management of malocclusion and Group-III (n=27; M=12, F=15)

included all subjects in whom non-extraction orthodontic treatment was considered. The description of three groups of subjects is described in Table 1.

The effect of premolar extraction and non-extraction orthodontic treatment on the angulation of third molar was evaluated on the orthopantomograms by the methods as suggested by Tarazona et al.⁹ and Jain et al.¹⁰ The outline of the sigmoid notch, ramus and body of the mandible and the outline of maxillary and mandibular third molars were traced on an acetate sheet. The line joining the lowest point of sigmoid notch bilaterally was considered as the horizontal reference plane.⁹ Subjects in whom the development of third molar germ had not reached Nolla's¹⁵ stage-6, the long axis of third molar was drawn as described in Fig. 1; and in subjects in whom third molar development was beyond Nolla's¹⁵ stage-6 of development, the long axis of third molar was drawn as mentioned in Fig. 2. The outer angle formed between long axis of third molar and the reference plane was measured to determine the third molar angulation as used by Jain et al.¹⁰ Pretreatment value was subtracted from posttreatment value to determine the change in angulation that occurred during the treatment. All the measurements were measured twice by a protractor by the same investigator (CY) and their mean was considered for statistical analysis.

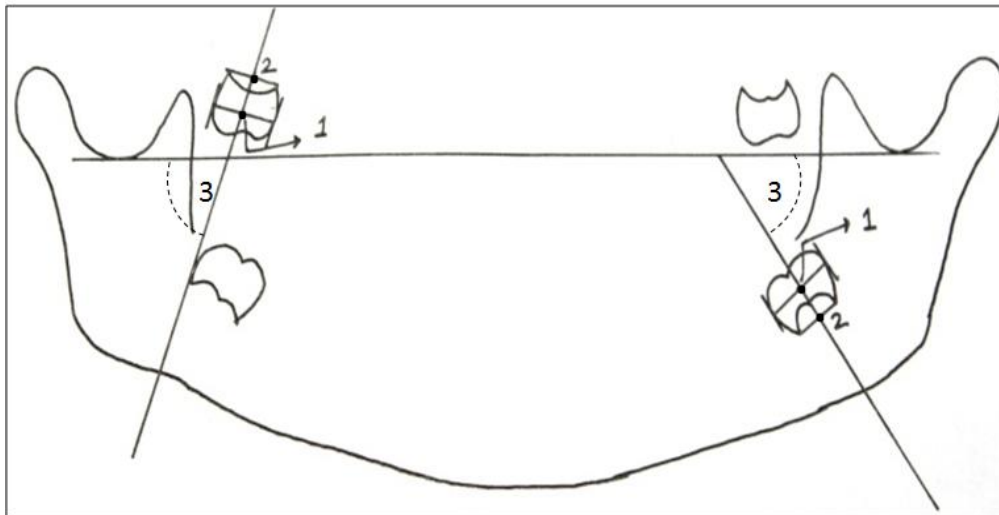


Fig. 1: Identification of long axis of the third molar when only the crown of the third molar is developed. The line joining the point-1 (the midpoint of line joining most convex point on mesial and distal contour of crown) and point-2 (the midpoint of line joining the mesial and distal cervical areas) was considered as the long axis of the third molar. The outer angle (3) was considered for measurement

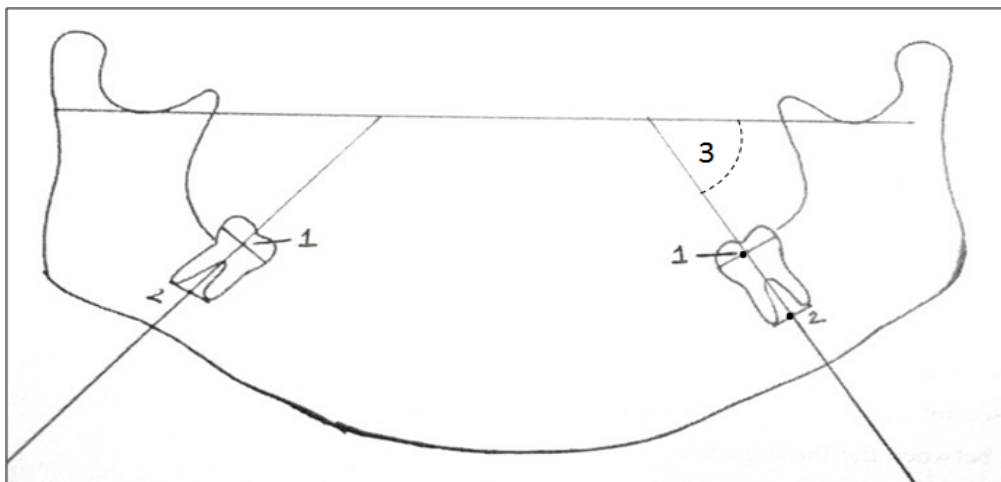


Fig. 2: Identification of long axis of the third molar when both the crown and root of the third molar is developed. The line joining the point-1 (the midpoint of the line joining the most convex points on the mesial and distal contour of crown) and point-2 (the midpoint of line joining mesial and distal root tips) was considered as the long axis of the third molar. The outer angle (3) was considered for measurement

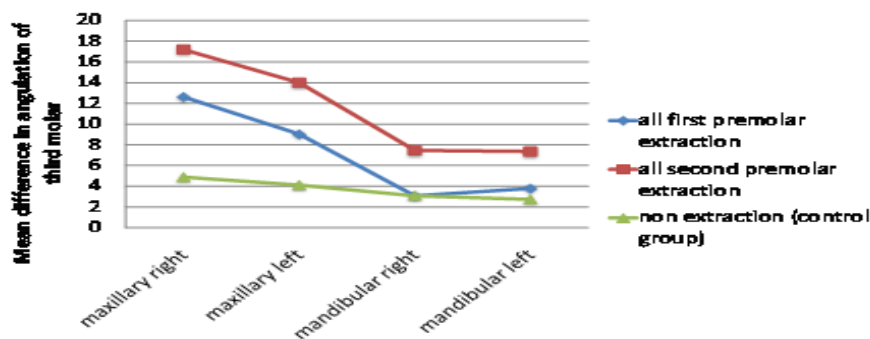


Fig. 3: The mean difference in the angulation of maxillary and mandibular third molars with respect to the horizontal reference plane in Group-I, Group-II and Group-III subjects

Table 1: Description of three groups of subjects included in the study

Description	Group-I (n=26)	Group-II (n=20)	Group-III (n=27)	Significance (P-value)
Mean age of the subjects (Yrs)	15.85±2.98	15.35±3.03	15.22±2.73	0.719 ^{NS}
Age range of the subjects (Yrs)	13-24	13-23	13-21	0.719 ^{NS}
Mean duration of treatment (Months)	28.12±6.17	30.30±5.33	24.85±5.85	0.008 ^{**}

NS=Non-significant, **=P<0.01

Table 2: Changes in the angulation of maxillary and mandibular right and left third molars among Group-I, Group-II and Group-III subjects

Groups	Variables	Pre-treatment Mean ± SD	Post-treatment Mean ± SD	Mean Difference Mean ± SD	Significance (P-value)
Group-I	Maxillary Right 3 rd Molar Angulation (°)	54.37±17.65	67.00±14.36	12.63±19.18	.010**
	Maxillary Left 3 rd Molar Angulation (°)	60.38±14.89	69.40±14.79	9.02±15.68	.010**
	Mandibular Right 3 rd Molar Angulation (°)	42.96±11.52	46.02±14.35	3.06±13.79	0.298 ^{NS}
	Mandibular Left 3 rd Molar Angulation (°)	47.94±10.92	51.71±11.20	3.77±13.28	0.178 ^{NS}
Group-II	Maxillary Right 3 rd Molar Angulation (°)	58.09±14.98	75.31±11.91	17.21±12.36	.001**
	Maxillary Left 3 rd Molar Angulation (°)	62.60±10.43	76.60±14.95	14.00±12.66	.001**
	Mandibular Right 3 rd Molar Angulation (°)	43.47±12.08	50.93±12.00	7.46±12.27	.034*
	Mandibular Left 3 rd Molar Angulation (°)	43.53±12.87	50.88±13.14	7.35±12.36	.026*
Group-III	Maxillary Right 3 rd Molar Angulation (°)	61.79±20.26	66.68±17.36	4.89±20.32	0.308 ^{NS}
	Maxillary Left 3 rd Molar Angulation (°)	66.10±13.43	70.20±14.16	4.10±15.59	0.254 ^{NS}
	Mandibular Right 3 rd Molar Angulation (°)	44.76±10.62	47.84±12.29	3.08±9.58	0.121 ^{NS}
	Mandibular Left 3 rd Molar Angulation (°)	44.18±12.24	46.91±14.73	2.72±10.69	0.245 ^{NS}

NS=Non-significant,*= P<0.05, **=P<0.01

STATISTICAL ANALYSIS

The statistical analysis was carried out using Statistical package for Social Sciences (SPSS Inc., Chicago, IL, version 15.0 for Windows). The descriptive statistics were used. The demographic characteristics and treatment duration of the three study groups were compared using chi-square test for nominal variables and one-way analysis of variance for continuous variables. Bonferroni test was used for multiple comparisons among the three groups. Paired t-test was used to calculate the significant difference in the angulation of third molars in each group. The P-value of 0.05 was considered as level of significance.

RESULTS

The assessment of intra-observer variability and reproducibility of landmark location and measurement errors were analyzed by retracing 10 randomly selected orthopantomograms after a gap of 7 days. The method error was calculated according to Dahlberg¹⁶ formula. To judge the reliability of the repeated tracing of chosen cephalometric landmarks, the method error was put in relation to the biological variance. The reliability of repeated measurements right and left maxillary and mandibular third molars ranged between 0.96 and 0.98.

The effects of premolar extraction and non-extraction orthodontic treatment on the angulation of developing

third molar is described in Table 2. The mean angulations of the maxillary right and left third molars were increased significantly by 12.63±19.18⁰ and 9.02±15.68⁰ respectively following first premolar extraction treatment (P<0.01). The mean angulations of the mandibular right and left third molars were increased marginally following first premolars extraction treatment and the differences were statistically not-significant. The mean angulations of the maxillary right and left third molars were increased significantly by 17.21±12.36⁰ and 14.00±12.66⁰ following second premolars extraction treatment (P<0.01). The mean angulations of the mandibular right and left third molars were also increased significantly by 7.46±12.27⁰ and 7.35±12.36⁰ following second premolars extraction treatment (P<0.05). The changes in the angulations of maxillary and mandibular third molars following non-extraction orthodontic treatment were very minimum and statistically not-significant. The comparison of pre-treatment and post-treatment changes in the angulation of maxillary and mandibular third molars among Group-I, Group-II and Group-III subjects on right and left side is shown in Fig. 3.

DISCUSSION

Third molars play an important role in orthodontics. If the eruption of third molars is predicted at an early age during the course of orthodontic treatment, then later

complications related to third molars can be avoided. The orthodontic treatment without premolar extractions showed significantly more eruption problems of wisdom teeth than those with premolar extractions and third molars in the non-extraction subjects were more frequently found in close relationship to the mandibular nerve compared to the extraction subjects.¹¹ Nance et al.¹⁷ suggested that if un-erupted third molars were more vertical, eruption to the occlusal plane was more likely than if the third molars were inclined more mesially. Thus if additional space can be created by extraction of premolars, third molars may be more likely to move upright to a vertical position as a prelude to eruption.

The age range of the subjects in the present study ranged from 13 to 24 years, with a mean age of 15.48 ± 2.88 years. During this time period, the third molar buds develop and also undergo important pre-eruptive rotational movements.¹⁸ Therefore, patients in this age group were selected to determine whether the extraction or non-extraction orthodontic treatment had any real favorable effect on the rotational uprighting and pre-eruptive movements taking place at that time. The mean age of the subjects included in three groups was comparable and thus eliminated the bias related to the effect of age on the growth occurring in the retromolar area among the three groups of subjects.¹⁰

The horizontal reference plane used in the present study was the line passing through the deepest point of sigmoid notch bilaterally as used by Tarazona et al.⁹ Since the sigmoid notch does not undergo any change during the course of orthodontic treatment therefore, this fixed reference plane was considered for the measurement of third molar angulation in the present study.

In this study, the orthopantomograms were used to measure third molar angulation as were used in many previous studies.^{9,10} Measurements of third molar angulation on lateral cephalograms, as seen in previous studies¹⁹⁻²² may have bias because of differences in the angulation between the superimposed images. Similar problems are also present in any cephalometric study of changes in posterior tooth positions and can only be overcome if measurements are made on 60-degree head films of the left and right sides, as shown by Richardson.²³ However, many studies have shown that panoramic radiographs are a reliable indicator in evaluating third molar positions.^{24,25}

We observed a significant uprighting of developing maxillary third molars as compared to the mandibular third molars following either first or second premolar extraction orthodontic treatment. The uprighting of the developing third molars on the right side was slightly more than on the left side in the maxilla. This could be due to more anchorage loss in the maxilla as compared to the mandible and also more on the right side of the maxilla as compared to the left side of the maxilla. The uprighting of third molars following second premolar extraction was more as compared to the first premolar extraction. This could be due to the more mesial

movement of the first and second molars following second premolar extraction which allowed more space for third molars to upright. Similar to our observation Tarazona et al.⁹ also reported more uprighting of the third molars following second premolars extractions. Eelsey and Rock¹² reported that extraction of lower premolars and orthodontic treatment to achieve complete closure of the space allowed the positions of many impacted lower third molars to improve significantly. However in contrast to our observation, Al Kuwari et al.¹³ reported significant improvement in the third molars angulation following first premolars extraction therapy compared to non-extraction orthodontic treatment. Russell et al.¹⁴ reported that either first or second premolar extraction had no significant effect in the uprighting of mandibular third molars but they observed higher proportion of mandibular third molars uprighting following second premolars extraction as compared to the first premolars extraction and non-extraction orthodontic treatment.

In contrast to premolars extraction orthodontic treatment, no significant improvement in the angulation of maxillary and mandibular third molars was found with non-extraction treatment. Slight improvement in the third molar angulation following non-extraction orthodontic treatment could be due to the growth related pre-eruptive movement of the third molars. Hence, the third molar angulations were more or less maintained in nonextraction group and showed very minimal improvement when treatment was done with the non-extraction technique. Similar to our observation, Jain et al.¹⁰ also noted a very minimal change in the angulation of third molars after non-extraction orthodontic treatment. However in contrast to our observation, Saysel et al.²⁶ found worsening of third molar angulations following non-extraction orthodontic treatment.

Thus from the present study it appears that orthodontic treatment with second premolar extraction resulted uprighting of the third molars which are more likely to erupt. However, the decision to extract either first or second premolars as a part of orthodontic treatment should primarily be based on the requirement of space at a particular site in the dental arch and secondarily to accommodate the third molars.

CONCLUSIONS

The null hypothesis was rejected and the following conclusions were drawn from the present study.

1. Extraction of first and second premolars had favorable effect on the angulation of developing third molars. The favorable changes were more following the second premolar extraction as compared to the all first premolar extraction.
2. The uprighting of the developing maxillary third molars was more as compared to the mandibular third molars following premolar extraction orthodontic treatment.

3. The uprighting of the developing third molars on the right side was more as compared to the left side following premolar extraction orthodontic treatment.

REFERENCES

1. Staggers JA, Germane N, Fortson WM. A comparison of the effects of first premolar extractions on third molar angulation. *Angle Orthod* 1992;62:135–38.
2. Forsberg CM, Vingren B, Wesslen U. Mandibular third molar eruption in relation to available space as assessed on lateral cephalograms. *Swed Dent J* 1989;13:23–31.
3. Lindqvist B, Thilander B. Extraction of third molars in cases of anticipated crowding in the lower jaw. *Am J Orthod* 1982;81:130-39.
4. Richardson ME. The role of the third molar in the cause of late lower arch crowding: a review. *Am J Orthod Dentofacial Orthop* 1989;95:79-83.
5. Richardson ME. Late lower arch crowding in relation to soft tissue maturation. *Am J Orthod Dentofacial Orthop* 1997;112:159-64.
6. Richardson ME. The etiology and prediction of mandibular third molar impaction. *Angle Orthod* 1977;47:165-72.
7. Begg PR, Kesling PC. *Begg Orthodontic Theory and Technique*. Philadelphia, Pa: Saunders; 1977.
8. Richardson M. Changes in lower third molar position in the young adult. *Am J Orthod Dentofacial Orthop* 1992;102:320–27.
9. Tarazona B, Paredes V, Llamas JM, Cibrián R, Gandia JL. Influence of first and second premolar extraction or non-extraction treatments on mandibular third molar angulation and position. A comparative study. *Med Oral Patol Oral Cir Bucal* 2010;15:e760-66.
10. Jain S, Valiathan A. Influence of first premolar extraction on mandibular third molar angulation. *Angle Orthod* 2009;79:1143-48.
11. Miclotte A, Van Hevele J, Roles A, Elaut J, Willems G, Politis C, Jacobs R. Position of lower wisdom teeth and their relation to the alveolar nerve in orthodontic patients treated with and without extraction of premolars: a longitudinal study. *Clin Oral Investig* 2014;18:1731-39.
12. Elsey MJ, Rock WP. Influence of orthodontic treatment on development of third molars. *Br J Oral Maxillofac Surg* 2000;38:350-53.
13. Al Kuwari HM, Talakey AA, Al-Sahli RM, Albadr AH. Influence of orthodontic treatment with first premolar extraction on the angulation of the mandibular third molar. *Saudi Med J* 2013;34:639-43.
14. Russell B, Skvara M, Draper E, Proffit WR, Philips C, White RP. The association between orthodontic treatment with removal of premolars and the angulation of developing mandibular third molars over time. *Angle Orthod* 2013;83:376-80.
15. Nolla CM. The development of the ten permanent teeth. *J Dent Child* 1960;27:254.
16. Dahlberg G. *Statistical methods for medical and biological students*. London: George Allen and Unwin; 1940. pp. 122-32.
17. Nance PE, White RP Jr, Offenbacher S, Phillips C, Blakey GH, Haug RH. Changes in third molar angulation and position in young adults and follow-up periodontal pathology. *J Oral Maxillofac Surg* 2006;64:424-28.
18. Richardson ME. Pre-eruptive movements of the mandibular third molar. *Angle Orthod* 1978;48:187–93.
19. Erdem D, Ozdiler E, Memikoglu UT, Baspinar E. Third molar impaction in extraction cases treated with the Begg technique. *Eur J Orthod* 1998;20:263–70.
20. Kim TW, Artun J, Behbehani F, Artese F. Prevalence of third molar impaction in orthodontic patients treated

nonextraction and with extraction of 4 premolars. *Am J Orthod Dentofacial Orthop* 2003;123:138–45.

21. Artun J, Thalib L, Little RM. Third molar angulations during and after treatment of adolescent orthodontic patients. *Eur J Orthod* 2005;27:590–96.
22. Behbehani F, Artun J, Thalib L. Prediction of mandibular third molar impaction in adolescent orthodontic patients. *Am J Orthod Dentofacial Orthop* 2006;130:47–55.
23. Richardson ME. The early developmental position of the lower third molar relative to certain jaw dimensions. *Angle Orthod* 1970;40:226–30.
24. Olive RJ, Basford KE. Transverse dento-skeletal relationships and third molar impaction. *Angle Orthod* 1981;51:41–47.
25. Larheim TA, Svanaes DB. Reproducibility of rotational panoramic radiography: mandibular linear dimensions and angles. *Am J Orthod Dentofacial Orthop* 1986;90:45–51.
26. Saisel MY, Meral GD, Kocadereli I, Tasar F. The effects of first premolar extractions on third molar angulations. *Angle Orthod* 2005;75:719–22.

How to cite this article: Yadav C, Utreja AK, Singh SP, Jena AK. Second premolar extraction improves the Angulation of Developing third molars better than first premolar extraction among subjects undergoing Comprehensive Orthodontic Treatment. *J Dent Specialities* 2016;4(1):46-51.

Source of Support: NIL

Conflict of Interest: All authors report no conflict of interest related to this study.