

Accuracy of different methods to determine working length in teeth with open apex – an ex-vivo comparative study

Priya Mittal,¹ Ganesh Ranganath Jadhav,² Ajay Logani.³

¹Senior Resident,

³Associate Professor,
Centre for Dental Education and Research,
All India Institute of Medical Sciences,
New Delhi, INDIA.

²Assistant Professor,
Department of Conservative Dentistry and
Endodontics,
Sinhgad Dental College & Hospital, Pune,
Maharashtra, INDIA.

Address for Correspondence:

Ajay Logani,
Associate Professor, Department of
Conservative Dentistry and Endodontics,
Centre for Dental Education and Research,
All India Institute of Medical Sciences,
New Delhi, INDIA.
E-mail: apexlogani@yahoo.co.in

Received: 28/12/2015

Accepted: 11/03/2016

ABSTRACT

Teeth with open apices present difficulty in estimation of working length because of extensive apical resorption and thin dentinal walls coupled with long-standing infection.

Aim: To comparatively evaluate the accuracy of a 6th generation apex locator, digital radiograph, paper point and tactile technique for their ability to determine the working length in teeth with open apices.

Methodology: Forty single-rooted maxillary anterior teeth were selected after excluding the teeth with curved roots. To simulate immature open apices, the apical 3–5 mm of the roots were removed such that ISO #80 file passed through the canal without any hindrance. The differences between dentinal-wall lengths in the same root was created using fine diamond round burs. Based on the method used to determine the working length, teeth were divided into five study groups and one control group as follows – Group I - radiographic measurement using paralleling technique, Group II - electronic working length measurement using Raypex 6 apex locator, Group III – tactile working length, Group IV – paper point working length and Group V - combination of apex locator, tactile and paper point techniques. In control group, actual working length was determined using direct observation of apical exit of file at shortest distance under dental operating microscope. Accuracy of all the methods to determine the working length was compared with the control group. The data was compiled and subjected to statistical tests and results were compiled.

Results: Within ± 0.5 mm, combined electronic, tactile and paper point working length (CETPPWL) method showed 99.5% of accuracy. Radiographic working length (RWL) using paralleling technique gave the least accurate result (around 78%) (n=40 for all groups).

Conclusion: In teeth with open apices working length determination is a challenge. No single method is accurate. Combination of use of apex locator, tactile and paper point method is recommended.

Key words: Open Apex, Working Length, Electronic Working Length, Tactile Working Length, Paper Point Technique.

INTRODUCTION

The term ‘open apex’ is used to indicate the presence of an exceptionally wide root canal at the apex. It is seen in immature teeth when root development ceases as a sequel of pulp necrosis due to trauma or caries.¹ In mature apex extensive apical resorption, root end resection² or over instrumentation may result in formation of open apex. It is clinically determined if an ISO size 80 file passes beyond the confines of the canal without any hindrance.^{3,4} Accurate working length determination is necessary in achieving optimal healing as is evident in epidemiological^{5,6} and histological studies.

Confinement of instrumentation and filling materials to the limits of the canal increases the success rate of root canal treatment as failure to do so may result in accidental extrusion of irrigant, dressing or filling with persistent periapical inflammation and postoperative pain.^{7,8,9} Open apices pose difficulties to contemporary methods of canal length determination.

In open apex, dentinal walls have irregular margins ending at different levels resulting in overestimation of the radiographic working length.¹⁰ Such teeth show shorter electronic working length than the actual canal length because wide root canal associated with open apices adversely influences the function of apex locators.^{11,12,13,14} Tactile technique can be used in open apices with better accuracy; however it has steep learning curve with vast inter-operative difference in measurement and difficulties in disengaging of the file tip from dentinal wall.¹⁵ In paper point technique, the canal needs to be completely dry and the periapical tissues to be relatively moist.¹⁰ The contact area of paper point to the inflamed

Access this article online	
Quick Response Code:	Website: www.innovativepublication.com
	DOI: 10.5958/2393-9834.2016.00008.5

periapical tissues is large, and excess moisture is common hence this technique results in measurement error.

Hence, there is a need to evaluate various methods to accurately determine working length with wide or immature apex. Aim of this study was to comparatively evaluate the accuracy of digital radiograph exposed with paralleling technique (RWL), 6th generation apex locator (EWL), tactile method (TWL), paper point method (PPWL), combined electronic and radiographic working length (CERWL) and combined electronic, tactile and paper point working length (CETPPWL) method to determine the working length in teeth with open apex.

MATERIALS AND METHODS

Sample collection and sample preparation: Forty single-canal maxillary anterior teeth were selected after excluding the teeth with curved roots (>10 degrees). All the extracted teeth were kept in 5.25% sodium hypochlorite for 2 hours and then stored in sterile 0.9% saline solution. The teeth were decoronated at the cemento-enamel junction with a diamond disc to simplify access to the root canal and to obtain a fixed occlusal landmark. To simulate immature open apices, the apical 3–5 mm of the roots was removed using diamond disc with slow speed such that ISO size 80 file passed through the canal without any hindrance. The apical resorption was simulated by creating irregular differences between dentinal-wall lengths in the same root using fine diamond round burs and ultrasonic tips. The differences between dentinal-wall lengths in the same root ranged from 2 to 5 mm.

Working lengths determination:

Control - Actual working length (AWL)

A size 15 K-file was progressed through the root canal to the level of the shortest dentinal wall (sdw) under X16 magnification in an endodontic microscope. A silicon stopper was adjusted to a coronal reference point. The length between file tip and stopper was taken as AWL.

Group I - Radiographic working length (RWL)

Each specimen was kept on the platform and was exposed to digital radiography keeping all parameters constant. XCP-DS digital sensor positioning device (Rinn XCP Instrument Kit, Dentsply, Elgin, IL Dentsply) was adapted to the X ray machine tube and was used for all teeth to keep uniformity in paralleling technique. ISO size 25 file was placed inside the root canal and was exposed to radiograph. Ingles method was used to determine the working length wherein it is kept 1-2mm short of radiographic apex.

Group II - Electronic working length (EWL)

Freshly mixed Alginate was poured into the disposable, plastic cylindrical container keeping space for tooth insertion and lip clip. Canal of each tooth was packed with cotton up to the root apex so as to prevent any unwanted retrograde entry of Alginate into the canal (Fig. 2). Excess alginate around the teeth and mould was trimmed with a scalpel blade. ISO size 15 size K-File was used to determine working length using Raypex 6 as per manufacturer instructions.

Group III - Tactile working length (TWL)

The aim of the Tactile Method is to circumferentially probe the dentinal walls with the bent tip of the file to determine the length of the shortest dentinal wall. ISO size 25 K-File file was bent at the tip (0.5–1 mm) to a 90° angle using an endodontic gauge (Dentsply Maillefer, Ballaigues, Switzerland). The bent file was placed against a dentinal wall in the root canal and displaced apically until it engaged the edge of dentinal wall at the apex (Fig. 1). The silicon ring was adjusted to a coronal reference point and the file was then rotated to disengage the bent tip. The same procedure was repeated to circumferentially probe all dentinal walls. When a shorter length was detected the silicon ring was readjusted and is kept as a tactile working length (TWL).

Group IV - Paper point working length (PPWL)

Red dye was prepared using erythrosine. Sponge soaked in red dye was adapted in plastic cylindrical container and alginate was poured on top of it so as to stabilize the tooth, keeping a space for tooth in the centre. Tooth was inserted in the centre in such a way that apical third of root was in the sponge. ISO size 80 paper point was slowly inserted in the canal and rechecked till the tip of paper point just becomes red. This was measured and kept as PPWL.

Group V – Combined electronic and radiographic working length (CERWL)

Working lengths were determined using Raypex 6 and digital radiographs and average of two values was taken.

Group VI – Combined electronic, tactile and paper point working length (CETPPWL)

Working lengths were determined using Raypex 6, tactile method and paper point techniques individually and average of all three values was taken as final reading.

Statistical evaluation

Data were analyzed using the Stata 11.0 software (Stata Corp, College Station, Texas, U.S.A.). Bland and Altman analysis was performed.

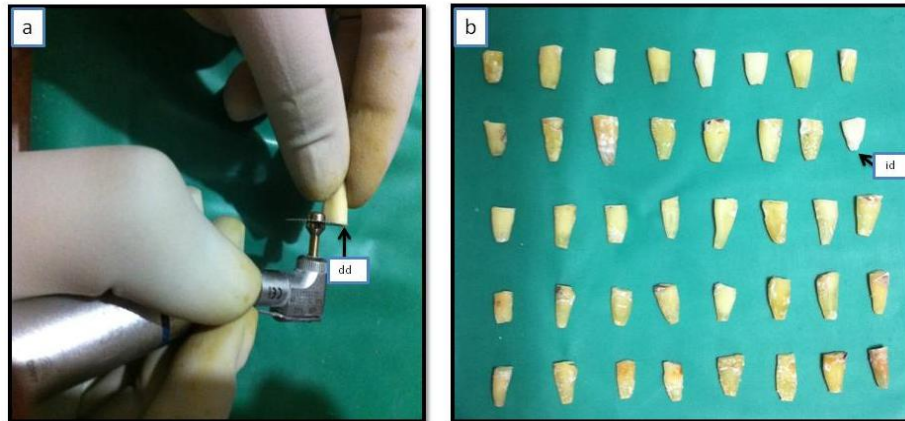


Fig. 1: All teeth were de-coronated at the cement-enamel junction (a) with a diamond disc (dd). (b) - Immature open apices were simulated by removing the apical 3–5 mm of the roots using a diamond disc with slow speed and the apical resorption was simulated by creating irregular differences (id) between dentinal-wall lengths using fine diamond round burs and ultrasonic tips




Fig. 2: (a) - A size 15 K-file was progressed through the root canal to the level of the shortest dentinal wall (sdw) under magnification. (b) - XCP-DS digital sensor positioning devise (pd) was adapted to the X ray machine tube and digital sensor (ds) was adapted in devise. (c) - ISO size 25 file was placed inside the root canal and was exposed to radiograph and the working length was determined using Ingles method




Fig. 3: (a) - ISO size 15 K-File was used to determine working using Raypex 6. (b) - ISO size 25 K-File file bent at the tip (0.5–1 mm) to a 90° angle was used in tactile method




Fig. 4: (a) - Sponge soaked in red dye was adapted in plastic cylindrical container. (b) Alginate was poured on top of it so as to stabilize the tooth, keeping a space for tooth in the centre. (c) Tooth was inserted in the centre in such a way that apical third of root was in the sponge. ISO 80 paper point was slowly inserted in the canal and re-checked till the tip of paper point just becomes red. (d) Paper point showing red tip




Fig. 5: In CETPPWL technique, Raypex 6 (a), tactile method (b) and paper point techniques(c) were used

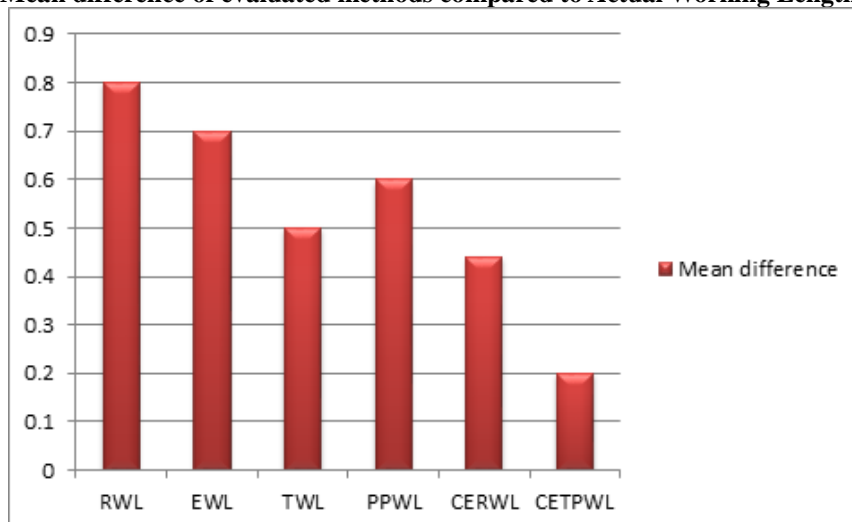
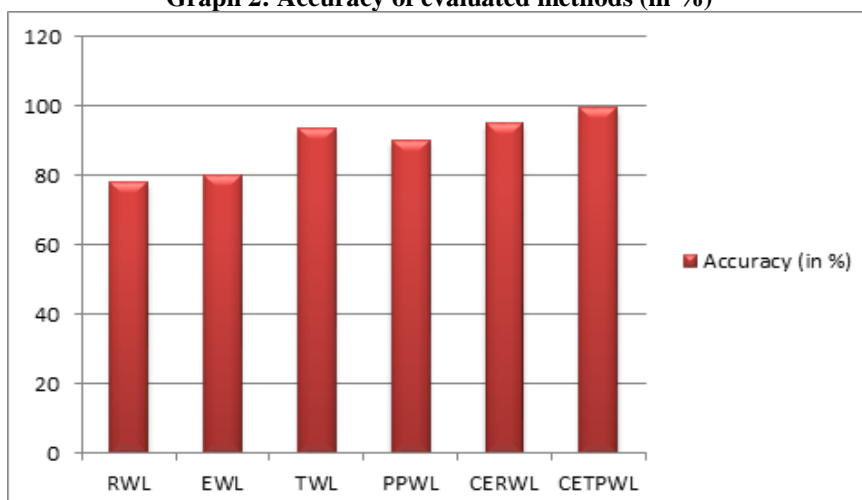
Results

The mean (mm), standard deviations (mm) and accuracy (in percentage) of each working length techniques are shown in Table 1. The difference of mean of distance measurement of AWL was found to be 0.8 for RWL, 0.78 mm for the Raypex 6, 0.5 mm for TWL, 0.6 mm for PPWL, 0.44 mm for CERWL and 0.2 mm for CRTPPWL (Graph 1). Bland and Altman analysis was done to compare all working length measurement techniques.

CRTPPWL technique was found to be the nearest match with the AWL. Within ± 0.5 mm, the accuracies were 78% for radiographic working length (RWL using paralleling technique), 80% for electronic working length (EWL using Raypex 6, a sixth generation apex locator), 93.5% for tactile working length (TWL using ISO 25 K file), 90% for paper point working length method (using ISO size 80 paper point), 95% for combined electronic and radiographic working length (CERWL) and 99.5% for combined electronic, tactile and paper point working length (CETPPWL) method (Graph 2) (n=40 for all groups).

Table 1: Table showing accuracy and mean difference of all working lengths with AWL

Method	Mean difference with AWL Mean \pm S.D	95% Conf. Interval	Accuracy (%)
RWL	0.8 \pm 0.44	(0.7 - 0.92)	78
EWL	0.7 \pm 0.32	(0.61 - 0.89)	80
TWL	0.5 \pm 0.20	(0.40 - 0.72)	94.5
PPWL	0.6 \pm 0.23	(0.43 - 0.75)	90
CERWL	0.44 \pm 0.27	(0.24-0.57)	95
CEPTWL	0.2 \pm 0.18	(0.09 - 0.35)	99.5

Graph 1: Mean difference of evaluated methods compared to Actual Working Length (± 0.5 mm)**Graph 2: Accuracy of evaluated methods (in %)**

Discussion

The open apex definition varies according to authors and is decided by the minimum ISO size file that can be passed freely through the apical foramen as ISO 100¹⁶ ISO 80^{3,4} ISO 60^{15,17}, ISO 45¹⁸ or ISO 40.¹⁹ Open apices can be classified based on a radiographic analysis as divergent, parallel and tapering.^[31] Mechanical instrumentation of the immature teeth with blunderbuss canal is difficult as it often leads to weakening and fracture of thin, lateral dentinal walls.^{20,21} More dependence should be on the use of copious irrigation and intra-canal medicaments like triple antibiotic paste, double antibiotic paste, calcium hydroxide etc. to disinfect the canal. In teeth with open apices root development in the labio-lingual plane lags behind that in a mesio-distal direction, so a parallel apex seen on a radiograph would appear more divergent if the image could be taken proximally.³ A precise measurement of the working length is critical for success. Its underestimation can lead to insufficient debridement of the root canal, whereas overestimation

may result in damage to the periapical tissues. These can delay or prevent healing. Hence in teeth with open apices, there is a need for comparing the various methods of working length determination and establishing the most accurate method.

Despite radiography being the main method of determining working length in teeth with open apices, numerous studies have reported variations in the radiographic technique.²² Radiographic working length is kept 1–2 mm^{23,24} or 2–3 mm²⁵ short of an estimated working length obtained from an undistorted pre-operative periapical radiograph. However this method has not been elaborated further in detailed.^{17,26} Use of the paralleling radiographic technique can result in an up to 7.58% over-estimation of the actual canal length with unintentional over-instrumentation.²⁷ In addition, variables, such as anatomical noise, the shape and orientation of the apex in relation to the X-ray beam, observer variability, film speed, and viewing conditions, such as the presence of extraneous light, can all influence the accuracy of radiographic working length

determination.^{28,29,30} Hence in the presented study RWL gave only 78% of accuracy.

Clinical performance of Raypex 6 (VDW, Munich, Germany), a sixth generation apex locator, was found to be successful in mature teeth.³¹ However, in the current study, its accuracy in open apices was found to be lower (80% of accuracy) which is identical to previous similar study in open apex.³² Various reasons attributed to the lower accuracy of apex locator in tooth with open apex are - the instruments not touching the canal walls, the impedance change at the apex would be far less abrupt in an immature tooth than a mature tooth etc. In the present study, the accuracy of tactile method was found to be high (93.5%) as documented in the previous study.¹⁵ However there are certain limitations of tactile technique such as difficulty in using file in curved canals, steep learning curve, difficulties in disengaging of the file tip from irregularly resorbed dentinal wall, high inter-operator discrepancy in readings etc. The paper point techniques may deliver accurate measurements provided that the periapical tissues exist at the same level of canal terminus and that moisture control is possible within the canal as well as from the periapical tissues which is highly impossible in every clinical scenario. Authors found an accuracy of 90% for the paper point technique when all measurements within ± 0.5 mm from the radiographic apex were considered accurate.

Radiographic method has least accuracy as the teeth with open apices has irregular margins and the smallest dentinal wall is to be considered as apical limit of preparation which is not possible due to 2 D representation of 3 D object. Electronic method has accuracy of 80%. Readings were higher in comparison to actual working length. Tactile working length had higher accuracy because it was able to physically verify the shortest wall circumferentially. However it has a limitation that it cannot be used in curved canal. Although paper point working length has high accuracy but it is subjected to give earliest reading due to continuous seepage from the canal. So, the combination method is accurate because it can overcome the shortcoming of each of the individual method. Dummer P et al (1984) suggested a combination of methods in open apex to increase the accuracy of working length determination. The European Society of Endodontology (2006) also recommended the use of an electronic apex locator (EAL) followed by confirmation of canal length with an undistorted radiograph during root canal treatment.³³ Hence in the presented study authors combined the three most accurate methods to increase the accuracy of working length determination technique in teeth with open apex which was found to be 99.5%.

Conclusion

Teeth with open apices present difficulty in estimation of working length by normally accurate, efficacious, conventional methods. A combination of electronic,

tactile and paper point methods in open apex increases the accuracy of working length determination.

References

1. Gutmann J, Heaton J. Management of the open (immature) apex. 2. Non-vital teeth. *Int Endod J* 1981;14:173-78.
2. Bogen G, Kuttler S. Mineral trioxide aggregate obturation: a review and case series. *J Endod* 2009;35:777-90.
3. Friend EA. Root treatment of teeth with open apices. *Proceedings of the Royal Society of Medicine* 1966;59:1035-36.
4. Moore A, Howley MF, O'Connell AC. Treatment of open apex teeth using two types of white mineral trioxide aggregate after initial dressing with calcium hydroxide in children. *Dental Traumatology* 2011;27:166-73.
5. Sjogren U, Hagglund B, Sundqvist G, Wing K. Factors affecting the long-term results of endodontic treatment. *J Endod* 1990;16:498-504.
6. Ng Y-L, Mann V, Rahbaran S, Lewsey J, Gulabivala K. Outcome of primary root canal treatment: systematic review of the literature - Part 2. Influence of clinical factors. *Int Endod J* 2008;41:6-31.
7. Ricucci D. Apical limit of root canal instrumentation and obturation, part 1. Literature review. *Int Endod J* 1988;6:384-93.
8. Ricucci D, Lange land K. Apical limit of root canal instrumentation and obturation, part 2. A histological study. *Int Endod J* 1988;6:394-409.
9. Holland R, Mazuqueli L, de Souza V, Murata SS, Dezan Junior E, Suzuki P. Influence of the type of vehicle and limit of obturation on apical and periapical tissue response in dogs' teeth after root canal filling with mineral trioxide aggregate. *J Endod* 2007;33:693-97.
10. Baggett FJ, Mackie IC, Worthington HV. An investigation into the measurement of the working length of immature incisor teeth requiring endodontic treatment in children. *Br Dent J* 1996;10:96-98.
11. ElAyouti A, Kimionis I, Chu AL, Lo'st C. Determining the apical terminus of root-end resected teeth using three modern apex locators: a comparative ex vivo study. *Int Endod J* 2005;38:827-33.
12. Ebrahim AK, Wadachi R, Suda H. Ex vivo evaluation of the ability of four different electronic apex locators to determine the working length in teeth with various foramen diameters. *Australian Dent J* 2006;51:258-62.
13. Herrera M, Abalos C, Planas AJ, Llamas R. Influence of apical constriction diameter on root ZX apex locator precision. *J Endod* 2007;33:995-98.
14. Tosun G, Erdemir A, Eldeniz AU, Sermet U, Sener Y. Accuracy of two electronic apex locators in primary teeth with and without apical resorption: a laboratory study. *Int Endod J* 2008;41:436-41.
15. ElAyouti A, Dima E, Löst C. A tactile method for canal length determination in teeth with open apices. *Int Endod J* 2009;42:1090-95.
16. Andreasen J, Andreasen F. *Essentials of Traumatic Injuries to the Teeth: a step-by-step treatment guide*, 2000; 2nd edn. Copenhagen: Munksgaard, 12.
17. Sarris S, Tahmassebi JF, Duggal MS, Cross IA. A clinical evaluation of mineral trioxide aggregate for root-end closure of non-vital immature permanent incisors in children- a pilot study. *Dental Traumatology* 2008;24:79-85.
18. Van Hassel H, Natkin E. Induction of root end closure. *J Dent Child* 1970;35:57-59.

19. Mente J, Hage N, Pfefferle T et al. Mineral trioxide aggregate apical plugs in teeth with open apical foramina: a retrospective analysis of treatment outcome. *J Endod* 2009;35:1354–58.
20. Jadhav GR, Shah N, Logani A. Comparative outcome of revascularization in bilateral, non-vital, immature maxillary anterior teeth supplemented with or without platelet rich plasma: A case series. *Journal of Conservative Dentistry* 2013; 16:568-72.
21. Jadhav GR, Shah N, Logani A. Revascularization with and without Platelet-rich Plasma in Nonvital, Immature, Anterior Teeth: A Pilot Clinical Study. *J Endod* 2012; 38:1581–87.
22. Kim Y-JA, Chandler NP. Determination of working length for teeth with wide or immature apices: a review. *Int Endod J* 2013;46:483–91.
23. Gilbert B. Endodontic treatment of the open apex. *Quintessence International* 1983;14:293–99.
24. Dummer P, McGinn J, Rees D. The position and topography of the apical canal constriction and apical foramen. *Int Endod J* 1984;17:192–98.
25. Whitworth J, Nunn J. Pediatric Endodontics. In: Welbury R, ed. *Pediatric Dentistry*, 2nd edn. Oxford: Oxford University Press, 2001; pp.172–73.
26. Yassen GH, Chin J, Mohammed Sharif AG, Alsofy SS, Othman SS, Eckert G. The effect of frequency of calcium hydroxide dressing change and various pre- and inter-operative factors on the endodontic treatment of traumatized immature permanent incisors. *Dental Traumatology* 2012;28:296–301.
27. Montes A, Gencoglu N. Canal length evaluation of curved canals by direct digital or conventional radiography. *Oral Surg Oral Med Oral Pathol Oral Radiol Endod* 2002;93:88–91.
28. ElAyouti A, Weiger R, Lost C. Frequency of over instrumentation with an acceptable radiographic working length. *J Endod* 2001;27:49–52.
29. Sheaffer JC, Eleazer PD, Scheetz JP, Clark SJ, Farman AG. Endodontic measurement accuracy and perceived radiograph quality: effects of film speed and density. *Oral Surg Oral Med Oral Pathol Oral Radiol Endod* 2003;96:441–48.
30. Orafi I, Worthington HV, Qualtrough AJE, Rushton VE. The impact of different viewing conditions on radiological file and working length measurement. *Int Endod J* 2010;43:600–07.
31. Moscoso S, Pineda K, Basilio J, Alvarado C, Roig M, Duran-Sindreu F. Evaluation of Dentaport ZX and Raypex 6 electronic apex locators: An *in vivo* study. *Med Oral Patol Oral Cir Bucal* 2014;19:e202-05.
32. Aydin U, Karataslioglu E, Aksoy F, Yildirim C. *In vitro* evaluation of Root ZX and Raypex 6 in teeth with different apical diameters. *J Conservative Dent* 2015;18:66-69.
33. European Society of Endodontology. Quality guidelines for endodontic treatment: consensus report of the European Society of Endodontology. *Int Endod J* 2006;39:921–30.

How to cite this article: Mittal P, Jadhav RG, Logani A. Accuracy of different methods to determine working length in teeth with open apex- an ex-vivo comparative study. *J Dent Specialities* 2016;4(1):39-45.

Source of Support: NIL

Conflict of Interest: All authors report no conflict of interest related to this study.