

## Idiopathic unilateral gingival enlargement: A case report

Preeti Sharma<sup>1\*</sup>, Shubhra Vaish<sup>2</sup>, Nikhil Sharma<sup>3</sup>

<sup>1</sup>PG Student, <sup>2</sup>Professor, <sup>3</sup>HOD, Dept. of Periodontology and Implantology, I.T.S- Centre for Dental Studies & Research Muradnagar, Ghaziabad, Uttar Pradesh, India

**\*Corresponding Author: Preeti Sharma**

Email: drpreetimds@gmail.com

### Abstract

Unilateral idiopathic gingival enlargement is characterized by huge enlargement of the gingiva. It can be an isolated entity or may be associated with any kind of syndrome. This is an unusual case report of a 16-year-old female patient who presented with a chief complaint of enlarged gums in relation to her left teeth in both maxillary and mandibular arches. The enlargement was slowly progressive since last 2 years. Intraoral examination revealed that there was unilateral, generalized, diffuse fibrotic gingival enlargement with pseudopockets. Patient was diagnosed with gingival fibrous hyperplasia based on the clinical, histological, and radiographic findings. The gingival enlargement was treated by conventional gingivectomy under local anaesthesia. The postoperative result was uneventful.

**Keywords:** Gingival Fibrous hyperplasia, External bevel gingivectomy, Laser.

### Introduction

The gingiva is the only clinically visible component of the periodontium inside the mouth. Gingiva is a part of oral mucosa which surrounds the neck of the teeth like a collar. It forms a tight seal around the teeth to support the bones and provide a barrier to bacteria. Gingival hyperplasia is an overgrowth of gingival tissue around the teeth and it is a rare condition which is characterized by slowly, progressive, non-hemorrhagic fibrotic enlargement of the gingiva. Gingival hyperplasia is also referred to as: Gingival fibromatosis, gingivomatosis, diffuse fibroma, idiopathic fibromatosis, hereditary gingival hyperplasia, gigantism of gingiva and hypertrophic gingiva.<sup>1</sup>

There are a number of causes for this condition, but it's often a symptom of poor oral hygiene or a side effect of using certain medications such as phenytoin, cyclosporine, and nifedipine. If left untreated, this oral condition can affect the alignment of your teeth and increase the risk of developing gum disease. Gingival fibromatosis may be an inherited condition or may be associated with medications or may be idiopathic. The gingival fibromatosis may occur as an isolated finding or be associated with one of several hereditary syndromes. The etiology is thought to be familial or idiopathic. The familial variation may occur as an isolated finding or be associated to one of several hereditary syndromes, e.g., Zimmermann-Laband, Murray-Puretic-Drescher, Rutherford, multiple hematomas, and cross syndrome. The exact cause of this abnormality is unknown.<sup>2</sup>

Gingival hyperplasia creates conditions favorable for the accumulation of plaque and debris increasing the depth of gingival sulcus and by interfering with adequate hygiene measures. Gingival hyperplasia causes aesthetic, functional, psychological and masticatory disturbances of the oral cavity. Nonsurgical periodontal therapy can partially reduce the size of the clinical lesions, mainly due to the elimination of bacteria. Hence, complete resolution of the lesion requires surgical intervention.<sup>3</sup>

This paper presents a rare case of a nonsyndromic idiopathic unilateral gingival enlargement and its management.

### Case Report

In the present case, a 16-year-old female reported to the Outpatient department of Periodontics, I.T.S CDSR, Muradnagar, with a chief complaint of swollen gums and inability to chew food from the left side of the jaw (Fig. 1 & Fig. 2). History revealed that the swelling was present since two years with no associated symptoms. It was slowly and progressively enlarged to its present size. The patient came for treatment only when the swelling started interfering with mastication. Patient gave history of unilateral mastication. The patient revealed no significant medical history and family history. Her current health condition and mental status were normal.

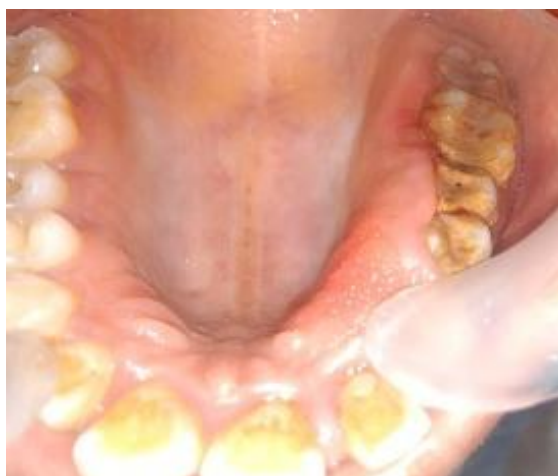General physical examination and extraoral examination was done to check for any facial anomalies and abnormalities in maxillofacial complex, but no abnormality was detected.

On intraoral examination, unilateral diffuse type of enlargement of gingiva was seen from mesial of first premolar to distal of second molar on the left side, both in maxillary and mandibular arch (Fig. 1&2). The right side of the oral cavity was unaffected. The enlargement involved the marginal, attached and the interdental gingiva. Both facial and lingual/palatal gingiva were affected but the enlargement was more on the palatal/lingual gingiva. The enlarged gingiva was smooth, pink in colour and exhibited no significant pain, little subgingival calculus and mild bleeding on probing. The enlargement was firm and fibrotic accompanied by an inflammatory component probably due to her inability to maintain adequate personal oral hygiene. The enlargement was also associated with an erythematous lesion in relation to palatal aspect of gingiva of left upper premolar (Fig. 3). The periodontal probing revealed deep pockets in relation to the involved teeth. Mobility of grade 1 was also present in all the involved teeth.

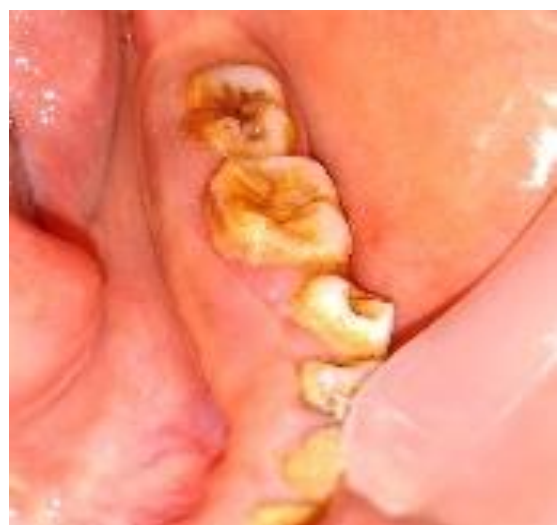Radiological Examination-Radiographic examination (OPG) revealed mild bone loss (Fig. 4).

Hematological Examination- Routine hematological investigations revealed hemoglobin 12.6% and differential leucocyte count of polymorphonuclear leukocytes 75%, lymphocytes 23%, monocytes 0%, eosinophils 2%, and basophils 0%.

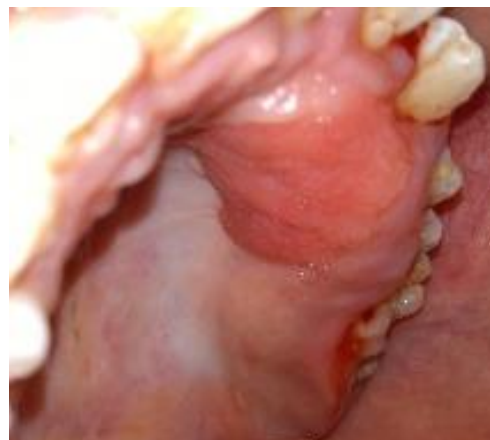Based on the history and clinical examination pubertal unilateral gingival enlargement due to hormonal changes was given as provisional diagnosis as age of initiation correlates with that. Since there was absence of abnormalities in extraoral examination association of syndrome with this condition was excluded.



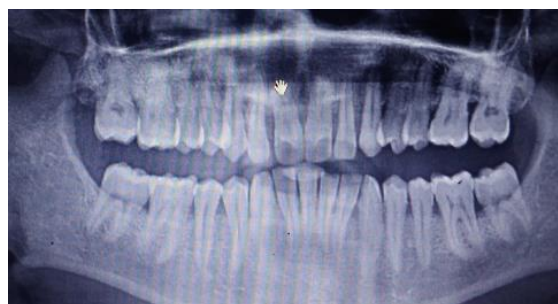**Fig. 1:** Pre operative view Gingival hyperplasia on left side of maxillary arch



**Fig. 2:** Pre operative view Gingival hyperplasia on left side of mandibular arch



**Fig. 3:** Enlarged maxillary palatal mucosa showing a erythematous lesion in relation to canine & 1<sup>st</sup> premolar



**Fig. 4:** OPG showing mild bone loss on the left side of the jaw

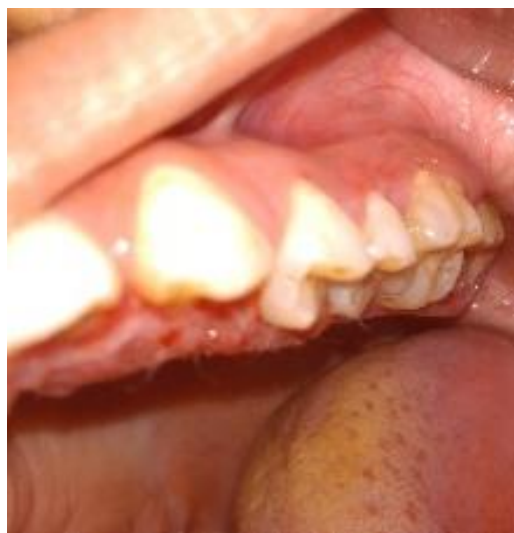### Treatment

After completion of Phase I treatment, the enlarged tissue was removed by the external bevel gingivectomy under local anesthesia. The pockets on each surface were explored with a periodontal probe and marked with a pocket marker. Each pocket was marked in several areas to outline its course on each surface. External bevel gingivectomy was carried out in both left maxillary and mandibular arches using Bard-Parker knives #11 and #15. The incision was started apical to the points marking the course of the pockets and was directed coronally to a point between the base of the pocket and the crest of the bone. The incision was beveled at approximately 45 degrees to the tooth surface. Excised tissue was removed using Gracey curettes and gingivectomy knives (Kirkland knife and Orban knife). Kirkland knife was used for incisions on the facial and lingual surfaces. Orbans periodontal knife was used for interdental incisions. The excised pocket wall was removed, area was cleaned with betadine and normal saline and the root surface was closely examined. The granulation tissue was carefully curetted, and any remaining calculus and necrotic cementum was removed. After the completion of gingivectomy, the reshaping of gingival margin was carried out by the soft tissue diode laser (Zolar Photon Plus diode laser) with 1 watt and the area was covered by periodontal dressing to reduce patient's discomfort. The excised tissue sample was sent for histopathological examination. Anti-inflammatory agent – Ibupara TDS were prescribed for one

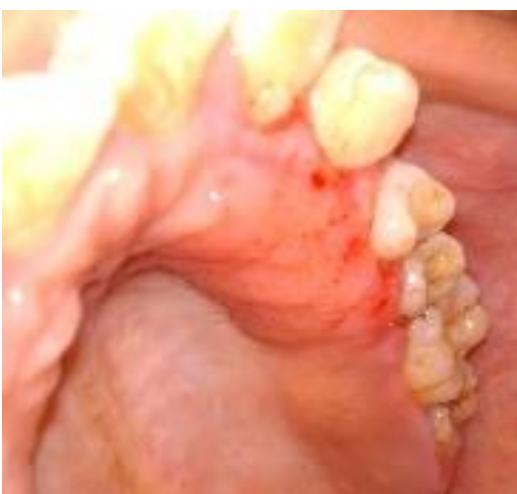week. Postoperative instructions were reinforced and patient was recalled after one week and then after one month for postsurgical evaluation. Periodontal dressing was removed after one week. Post-surgical healing was uneventful. Patient was satisfied with the result.

The patient was followed up regularly at 1 week, 1 month, 3 month, and 6 months interval followed by after 1 year. There was no recurrence of the lesion at the end of 1 year in this case (Fig. 5-11).

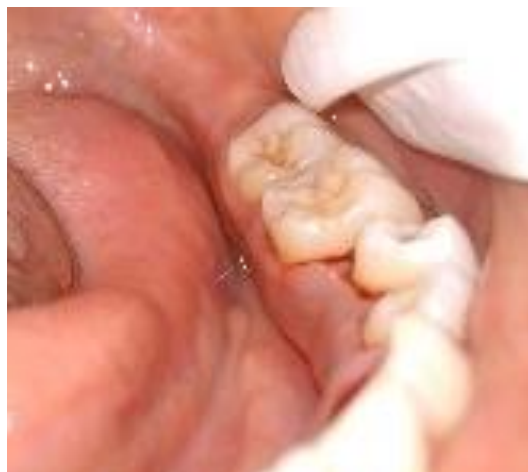Histopathological examination showed stratified squamous epithelium supported by fibrocellular connective tissue stroma. The stroma was composed of mild inflammatory cells, thick and thin bundles of collagen associated with numerous plump fibroblasts. These finding suggested the diagnosis of fibrous hyperplasia (Fig. 12 & 13).



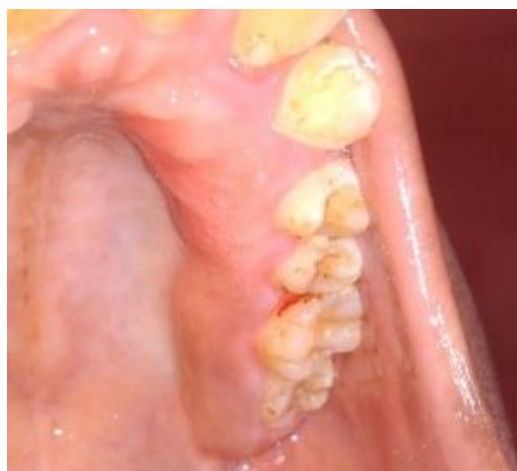**Fig. 5:** Post operative view buccal aspect of left maxillary gingiva



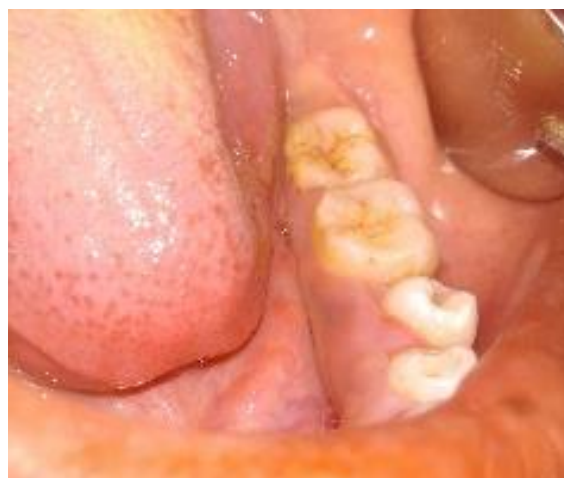**Fig.6:** Post operative view palatal aspect of left maxillary gingiva after gingivectomy (after 1 week)



**Fig. 7:** Post operative view lingual aspect of left mandibular gingiva after gingivectomy

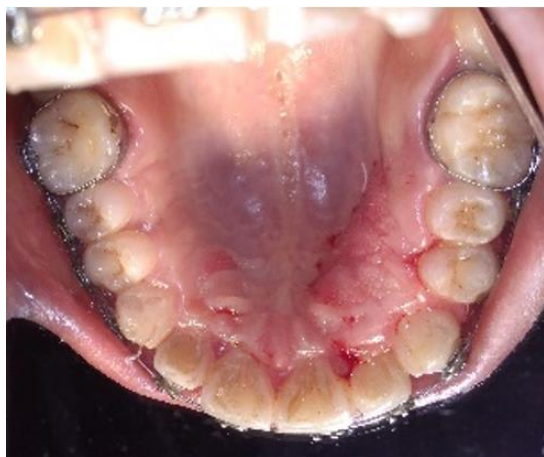

**Fig. 8:** Post operative view of left maxillary gingiva after one month

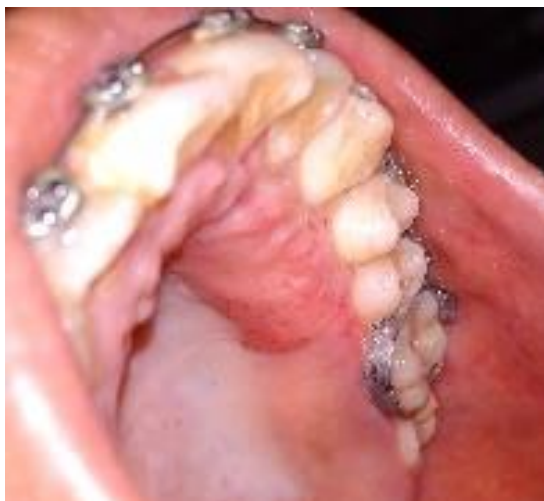

**Fig. 9:** Post operative view of mandibular gingiva after 1 month

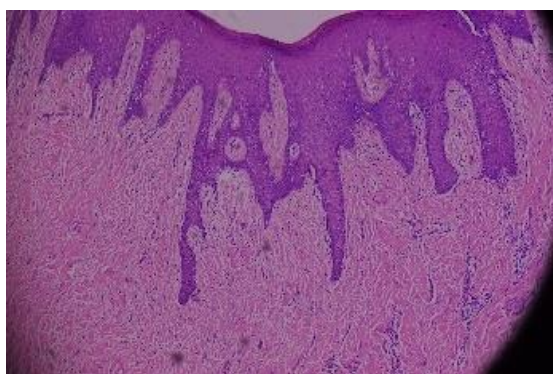




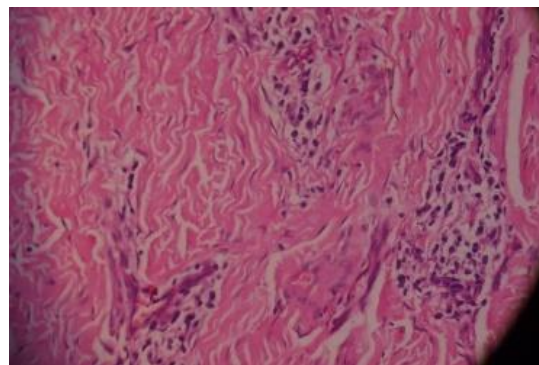
**Fig. 10:** Post operative view of left maxillary gingiva after 6 months



**Fig. 11:** Post operative view of left maxillary gingiva after 1 year



**Fig. 12:** Histopathological specimen under  $\times 10$  magnification showing stratified squamous epithelium with long slender rete-pegs, connective tissue, and dense collagen stroma



**Fig. 13:** Histopathological specimen under  $\times 40$  magnification showing connective tissue having numerous fibroblast and inflammatory cells

### Discussion

This paper reported a case of idiopathic gingival enlargement on left maxillary and mandibular arch. Gingival hyperplasia characterized by slowly progressive, non-hemorrhagic, fibrous enlargement of maxillary and mandibular gingival tissue. Gingival enlargement is mostly due to various drugs, local conditions such as poor oral hygiene, food impaction, or mouth breathing, syndromes, and hereditary disorders.<sup>4</sup> The clinical and histological features and systemic examination excluded the diagnosis of neoplastic enlargement in this case. Gingival hyperplasia can occur after therapy with drugs like phenytoin, cyclosporine and nifedipine. In this case, Patient did not give any kind of drug history.

The etiology and pathogenesis of gingival hyperplasia is still not well established, however it could be directly linked to three factors: individual susceptibility, local factors (dental plaque, caries, and iatrogenic factors) and the action of chemical substances and their metabolites. Patient's pubertal age and unilateral mastication habit were also the predisposing factors for the gingival enlargement in this case. According to some recent studies, rapid proliferation rate of fibroblast cells, increase in collagen synthesis and decreased levels of matrix metalloproteinases (MMP-1 and MMP-2), may be associated with this condition.<sup>5,6</sup>

Use of laser provided excellent hemostasis and better immediate postoperative result. Also the patient acceptance towards the treatment was better with the combination approach. M Elakabaki presented a case report on laser gingivectomy and found diode laser to be very safe and useful for esthetic periodontal soft-tissue management.<sup>7</sup>

Treatment methods for gingival enlargement are dependent on the severity of the lesion.<sup>1</sup> When the enlargement is minimal and possible to maintain by the patient, scaling and root planning along with proper maintenance of oral hygiene may be sufficient but when enlargement is massive, surgical intervention such as internal bevel or external bevel gingivectomy, electrocautery, and lasers can be used.<sup>8</sup> In this case report, gingival enlargement was satisfactorily treated with nonsurgical periodontal therapy including oral hygiene

instruction and oral prophylaxis followed by surgical excision of enlarged gingival tissue by the technique of external bevel gingivectomy and reshaping of gingival contour by a soft tissue diode laser.

Recurrence is a common feature over varying periods after surgical intervention of gingival enlargement. In this case report, there was no recurrence of the lesion even after 1 year of follow-up. Similarly several case reports were presented with no recurrence after more than one year of follow up.<sup>9</sup> Healing was uneventful and patient was satisfied. Patient was told about recurrence and was instructed to follow routine oral hygiene measures strictly to prevent recurrence.

**Financial or other Competing Interests:** None.

**Conflict of Interest:** None.

### References

1. Nagarale GP, Ravindra S, Thakur S, Setty S. Long term follow up of idiopathic gingival enlargement associated with chronic periodontitis: A case report and review. *J Indian Soc Periodontol* 2013;17:242-7.
2. Nitta H, Kameyama Y, and Ishikawa I. Unusual gingival enlargement with rapidly progressive periodontitis. Report of a case. *J Periodontol* 1993;64:1008-112.
3. Kantarci A, Cebeci I, Tuncer O, Carin M, Firatli E. Clinical effects of periodontal therapy on the severity of cyclosporin A-induced gingival hyperplasia. *J Periodontol* 1999;70:587-93.
4. Bittencourt LP, Campos V, Moliterno LF, Ribeiro DP, Sampaio RK. Hereditary gingival fibromatosis: Review of the literature and a case report. *Quintessence Int* 2000;31:415-8.
5. Shirasuna K, Okura M, Watatani K, Hayashido Y, Saka M, Matsuya T. Abnormal cellular property of fibroblasts from congenital gingival fibromatosis. *J Oral Pathol* 1988;17:381-5.
6. Coletta RD, Almeida OP, Reynolds MA, Sauk JJ. Alteration in expression of MMP-1 and MMP-2 but not TIMP-1 and TIMP-2 in hereditary gingival fibromatosis is mediated by TGF-beta 1 autocrine stimulation. *J Periodontol Res* 1999;34:457-63.
7. Elakabawi M. "Case Report: Laser Gingivectomy". *EC Dent Sci* 2017;13(3):112-5.
8. Coletta RD, Graner E. Hereditary gingival fibromatosis: a systematic review. *J Periodontol* 2006;77(5):753-64.
9. Bansal A, Narang S, Sowmya K, and Sehgal N. Treatment and two year follow up of a patient with hereditary gingival fibromatosis. *J Indian Soc Periodontol* 2011;15:406-9.

**How to cite the article:** Sharma P, Vaish S, Sharma N. Idiopathic unilateral gingival enlargement: A case report. *J Dent Specialities* 2019;7(1):56-60.