

Apicoectomy: An elucidation to a hitch

Shashant Avinash^{1*}, Eiti Agrawal², Iqra Mushtaq³, Anuva Bhandari⁴, Farheen Khan⁵, Thangmawizuali⁶

¹⁻⁶PG Student, Dept. of Periodontology and Implantology, ^{1,3}Divya Jyoti College of Sciences and Research, Modinagar, Uttar Pradesh, ^{2,4,5,6}I.T.S.- Centre for Dental Studies & Research, Muradnagar, Ghaziabad, Uttar Pradesh, India

***Corresponding Author: Shashant Avinash**

Email: drsavinash@gmail.com

Abstract

Endodontic surgery is a safe and passable alternative when teeth are not responding to traditional endodontic therapy and don't acquire favourable outcomes. Apicoectomy involves surgical management of a tooth with a periapical lesion which cannot be resolved by routine endodontic treatment. Because the term "apicoectomy" consists of only one aspect of a multifaceted series of surgical procedures, i.e. removal of root apex, the terms "periapical surgery" or "periradicular surgery" are more apposite. It must only be applied in specific situations. Endodontic treatment failures can be related to: extra-radicular infections such as periapical actinomycosis; to foreign body reactions that can be caused by endodontic material extrusion; to endogenous cholesterol crystal accumulation in apical tissues and unresolved cystic lesion.

Keywords: Apicoectomy, Root resection, Surgery, Tooth.

Introduction

Apical surgery is the standard endodontic surgical procedure to maintain a tooth with significant periapical lesion that cannot be treated with conventional endodontic re-treatment. When any non-surgical or conventional endodontic treatment fails, apical surgery or apicoectomy is the procedure which is mostly conducted as retreatment.

Indications for apical surgery have been updated in the past by the ESE (European Society of Endodontology, 2006) and it includes the following:¹

1. Radiological findings of apical periodontitis and/or symptoms associated with an obstructed canal (the obstruction proved not to be removable, displacement did not seem feasible or the risk of damage was high).
2. Extruded material with clinical or radiological findings of apical periodontitis and/or symptoms continuing over a prolonged period.
3. Persisting or emerging disease following root-canal treatment when root canal re-treatment is inappropriate.
4. Perforation of the root or the floor of the pulp chamber and where it is impossible to treat from within the pulp cavity.

The most adopted surgical methods to solve any endodontic failures, accidents and complications of any conventional treatment are: curettage with periapical planning, apicoectomy, apicoectomy with retro-filling, apicoectomy with retro-instrumentation and canal retro-filling and filling simultaneous to surgery.²

Apicoectomy involves the surgical removal of tooth root apex or root end resection which can be done alone or in combination with placing a retrograde filling in order to seal the apical part of the root.³ In the year 1884, apicoectomy procedure was well described and defined by J. Farrar⁴ as "a bold act, which removes the entire cause [of disease] and which will lead to a permanent cure which may not be the best in the end, but the most humane." According to Black,⁵ the root-resection technique i.e. amputation of the root apex has been originated as a treatment for "pyorrhoea

alveolaris" complicated by a dental abscess in the late years of the 19th century as a valid alternative to a dental extraction. Apicoectomy (root resection or root amputation) signifies the removal of the apices of pulpless teeth in which satisfactory root or pulp canal therapy has been performed. This operation is performed to remove known or unknown infection, granulation tissue or cystic areas that involve these teeth; yet retaining the major portion of the roots in situ.⁶ Thus, the success relies on different factors and is verified through clinical and radiographic evaluations during follow up.⁷⁻⁹

According to Weine, indications for tooth resection are:¹⁰⁻¹³

1. Severe vertical bone loss involving only one root of multi-rooted teeth
2. Through and through furcation involvement
3. Unfavourable proximity of roots of adjacent teeth
4. Preventing adequate hygiene maintenance in proximal areas
5. Severe root exposure due to dehiscence

Endodontic and restorative indications for apicoectomy are:

- a. Prosthetic failure of abutments within a splint. For example, if a single or multirooted tooth is periodontally involved within a fixed bridge, instead of removing the entire bridge, if the remaining abutment support is sufficient, the root of the involved tooth is extracted.
- b. For endodontic failure, hemi-section is useful in cases in which there is perforation through the floor of pulp chamber or pulp canal of one of the roots or an endodontically involved tooth which cannot be instrumented, and
- c. Vertical fracture of one root. However, the prognosis of vertical fracture is futile. If vertical fracture traverses one root while the other roots are unaffected, the offending root may be amputated.

Along with all these, apicoectomy is also indicated in severe destructive processes which may occur as a result of furcation or sub-gingival caries, traumatic injury and large root perforations during endodontic therapy.

Contraindications of apicoectomy include:

- Strong adjacent teeth available for bridge abutments as alternatives to hemisection
- Inoperable canals in root to be retained
- Fused roots making separation impossible
- The tooth has no function (no antagonist, no strategic importance serving as a pillar for a fixed prosthesis)
- Unrestorable tooth
- Periodontally compromised tooth and
- An uncooperative patient or a medically compromised patient for an oral surgical intervention.¹⁴

In the present report, we describe patients who had undergone apicoectomy because of failure of the conventional endodontic treatment. Our aim was to maintain a tooth by performing a surgical procedure that has a periapical lesion to eliminate any extra-radicular infection, foreign body material or cystic tissue.

Case Description

The ethical approval for this study was obtained from DJ College institutional ethical committee and informed consent was obtained from the patients.

Population

The present study involved 3 patients who had undergone unsuccessful conventional endodontic treatment. Radiographic images of the case suggested a persistent injury in the periapical region of the root. The patients included were in the age group of 25-32 years. The systemic anamnesis of all patients were non-contributory.

Surgical Procedure

The procedure of apicoectomy was planned and performed in all patients by the same surgeon. Firstly, the perioral soft tissues were cleaned, washed and painted with povidone-iodine in order to minimize contamination of the surgical wound. Under local anaesthesia with lidocaine HCl 2% injection [1:100000], the most commonly used mucoperiosteal flap, trapezoidal flap was performed for apical access in the anterior region with an obvious mesial and distal releasing incision. Once the full thickness flap was raised to expose the apical abscess, degranulation of the site was performed to locate the root end. On exposure, the root end was denuded off the cortical bone which eliminated the use of bur. The periapical pathological tissue was curetted properly to enhance the accessibility and visibility of the surgical field. Subsequently, root end resection was completed followed by formation of small retrocavity at the root end. After isolation of the surgical area, obturation was performed and IRM (Endomethasone N, Septodont, France) was used as root end sealing material in order to provide a tight apical seal. All the surgical sites were closed and secured using 3-0 sutures followed by placement of periodontal dressing Coe-Pak™ (GC America COE-PAK).

Case 1

A 28 year old female patient presented with a chief complaint of pain in tooth #21. After proper clinical and radiographic examination, a large periapical radiolucency was observed at the apex suggestive of a failed endodontic treatment in the referred tooth. As this periapical radiolucency was not resolved with conventional endodontic treatment, apicoectomy procedure was performed. The radiograph was taken immediately after obturation and the case was followed up after four months (Fig 3a-3e).

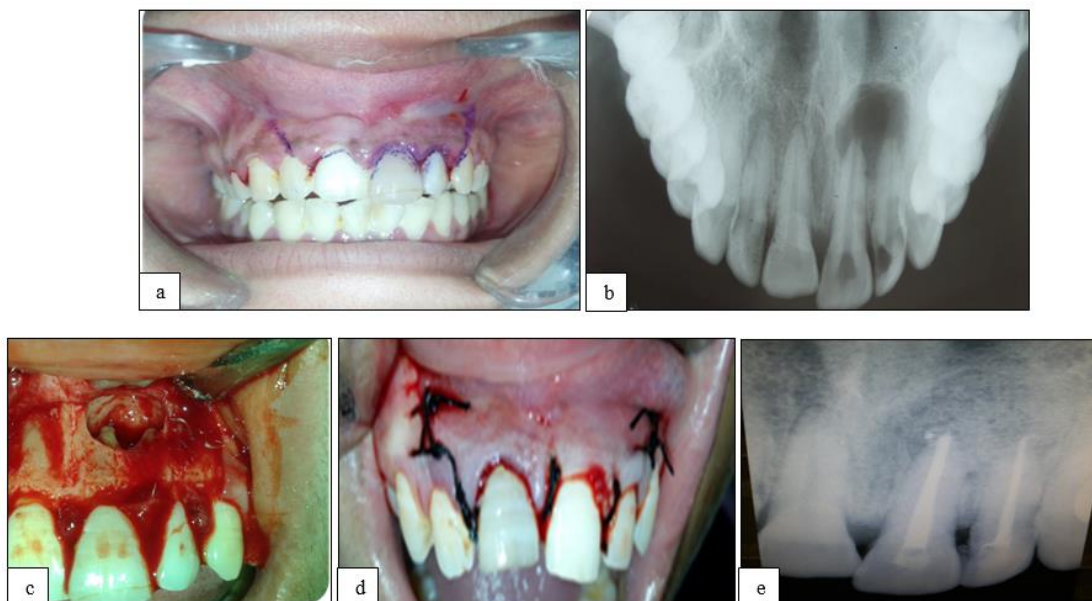


Fig. 1a: Preoperative #21; **b:** Preoperative radiograph; **c:** Flap raised and defect exposed; **d:** Suturing done; **e:** Radiograph after 3 months

Case 2

A 26 year old female patient presented with pain in tooth #41. The clinical and radiographic examination was done and an unsatisfactory endodontic treatment was confirmed in the tooth in question. The radiographic findings suggested a persistent injury in the periapical region of the

tooth. To treat the injury, it was decided to perform an apicoectomy on the respective tooth (Fig 2a-2f). The apicoectomy procedure was performed and radiograph was taken immediately after obturation. The follow-up radiograph was taken after four months.

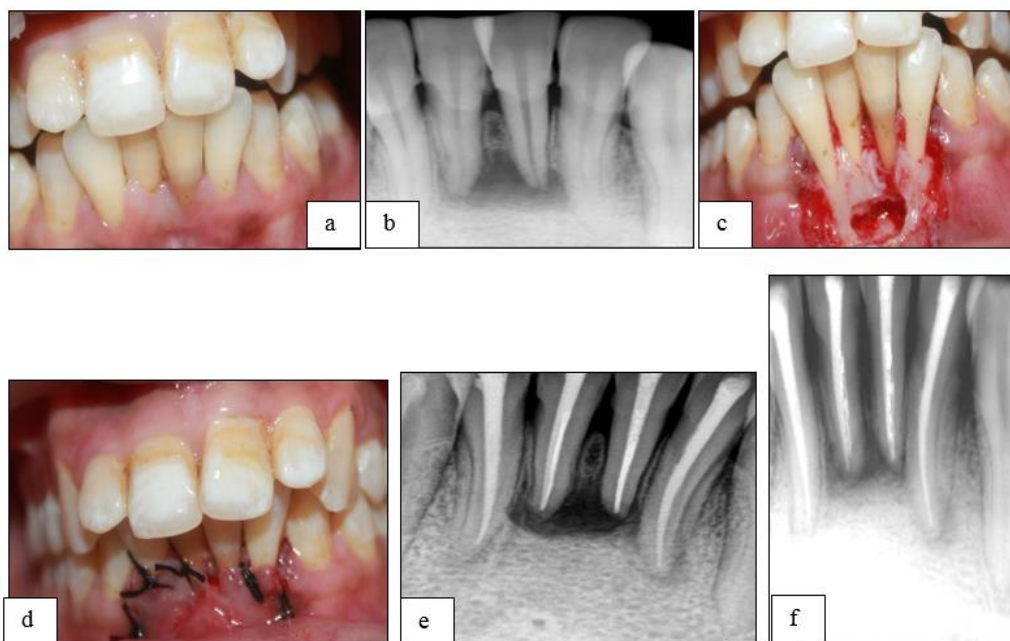


Fig. 2a: Preoperative #41; **b:** Preoperative radiograph; **c:** Flap raised to expose the defect; **d:** Suturing done; **e:** Post-obturation radiograph

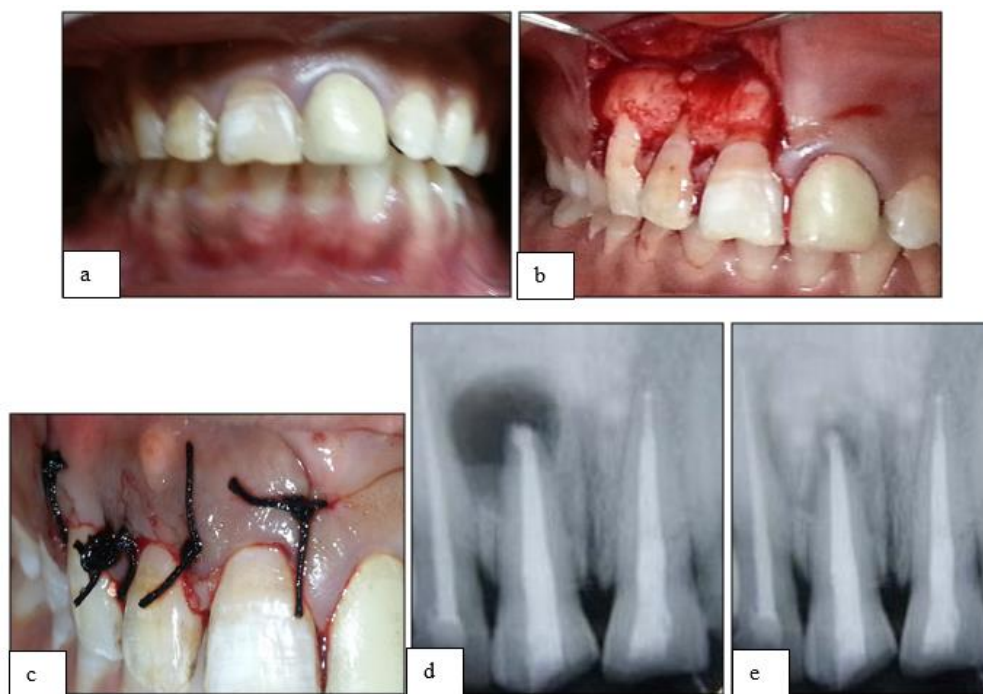


Fig. 3a: Preoperative #11; **b:** Flap raised and defect exposed; **c:** Suturing done; **d:** Immediate post-obturation radiograph; **e:** After 4 months

Post-Operative Instructions

Tablet Zerodol P (BID×3 days) was prescribed as an analgesic. Antibiotics were not recommended since the infection rate following endodontic surgery is lower. Oral hygiene procedures were instructed such as careful brushing and flossing (to begin after 24 hours). Proper nutrition and fluids were advised along with chlorhexidine rinse twice a day. However, Seymour et al (1986) conducted a study regarding post-operative pain after apicoectomy and concluded that it is of short duration and reaches its maximum intensity in the early postoperative period.¹⁵

Suture Removal and Evaluation

Sutures were removed 4 days after the surgery as short periods are preferred to enhance healing. There was indication of primary wound closure. Follow-up visits were at 4 weeks, post removal of sutures, at 4 months and at 6 months. The post-operative healing was classified as complete, partial healing (incomplete), uncertain, and no healing (or failure).¹⁶⁻¹⁸

Results

Post 4 months, no fistula formation or painful symptoms were observed. Periapical bone repair was confirmed by periapical radiographs. A CBCT (Cone beam computed tomography) image taken after 6 months showed a radiolucent image, interpreted as fibril healing.

Discussion

The most conventional or historical pathway to current surgical endodontic procedures and their applications has been tortuous and complex. Many newer techniques, defined as “revolutionary” that are being practiced today are simply re-interpretation of surgical concepts that were lost in the archives of time.¹¹ Among all these concepts, apical surgery proves to be the best resort to preserve natural teeth after its failed endodontic treatment.^{19,20}

The most common reasons cited for failure of endodontic therapy are, the absence of root-end filling and incorrect root end preparations.²¹ In 1930, Coolidge emphasized the importance of a well-sealed root canal prior to apicoectomy. Grossman referred to root amputation as dental proof of the old adage, “half a loaf is better than none”.²² The apical portion was cut at 45° to the long axis of the tooth. Regardless of some authors¹⁰ who advocate that larger the cut angle, larger will be the dentinal tubule exposure, this inclination degree was needed to allow total root surface exposure, aimed at facilitating the requisite operative procedures.

The use of modern surgical techniques and equipments has resulted in an increase in the success rate upto 92% for the same procedure.^{23,24} Nevertheless, the chances of failure of the apicoectomy procedure may be attributed to several factors. For instance, Leonardi et al.²⁵ suggested that the drill type employed at the root apex, or laser execution, as well as the cut angle may influence the post-operative results. Hence, it is vital to obtain the cut surface as regular as possible. Also, the apical cut must involve anatomical

variations such as the presence of isthmuses and accessory canals as these act as a reservoir for bacteria and necrotic pulp tissue, which can lead to treatment failure.

Regarding apical filling materials, a number of biocompatible materials have been introduced like MTA, Super EBA, and IRM. Nowadays, Guided tissue regeneration (GTR) techniques have also been projected as an adjunct with the intention to promote healing after periapical surgery.^{23,26}

Tortorici et al²⁷ in 2014 compared the outcomes of traditional apicoectomy [trapezoidal flap and retrograde obturation with silver amalgam (without zinc non Ygamma-2)] with modern apicoectomy [MTA (ProRoot [gray]; Dentsply Tulsa Dental, Johnson City, TN), as root-end filling material] by means of a controlled clinical trial with 5-year follow-up. They investigated 938 teeth in 843 patients and put forward that modern apicoectomy has a 5 times higher success rate (odds ratio, 5.20 [95% confidence interval, 3.94Y6.92]; P G 0.001) compared with the traditional technique. In the present study, the traditional technique with different filling material was used, increasing its chance towards more success.

In recent times, GTR techniques i.e. use of bone graft along with barrier membranes in adjunct to endodontic surgeries has been used to promote bone healing. Bernabé et al²⁸ reported a case of peri-radicular surgery with a combination of MTA and bovine bone graft and a cortical collagen membrane. They suggested that this procedure can be used to save teeth with questionable prognosis and is also favourable for osseous healing. It also aids in the regeneration of bone, periodontal ligament and cementum after periapical surgery.

Apicoectomy procedure can also be executed in the process of autotransplantation of an immature tooth. Jakse et al in 2018²⁹ reported autotransplantation of lower premolar, in which the apicoectomy procedure i.e cutting the root tip of an almost fully developed tooth was proved to be successful leading to improvement of the tooth prognosis. The clinical and radiologic follow-up examinations were done for up to 18 months. Autotransplantation along with intraoperative apicoectomy actually helps in revascularization and uneventful periodontal regeneration.

In order to prove its success rate, Raedel et al in 2015³⁰ conducted a retrospective study to measure the outcome of apicoectomies under practice conditions by mining an insurance database. They traced a total of 93,797 teeth in 77,636 patients after apicoectomy and evaluated the tooth survival rate at first, second and third years after surgery. The cumulative 3-year survival rate was found to be 81.6% among which the anterior teeth showed a significantly higher survival rate (84.0%) compared to posteriors. They postulated that teeth which were treated with apicoectomies are acceptable and successful for an intervention that was primarily conducted as retreatment after the failure of conventional root canal treatment.

Conclusion

Based on the contemporary understanding of endodontic concepts for success and failure, assessment and subsequent treatment of apicoectomy procedures have greatly improved. Advances in apicoectomy armamentaria and materials have enabled endodontists to treat challenging cases with much greater efficacy. The surgical technique which has been applied in this case i.e. apicoectomy, was appropriate and the results were satisfactory.

Conflict of Interest: None.

Financial or other Competing Interests: None.

References

- 1 European Society of Endodontology. Quality guidelines for endodontic treatment: consensus report of the European Society of Endodontology. *Int Endod J* 2006;39(12):921-30.
- 2 Orso VA, Filho MS. Cirurgia Parendodôntica: quando e como fazer. *R. Fac Odontol Porto Alegre Porto Alegre* 2006;47(1):20-3.
- 3 el-Swiah JM, Walker RT. Reasons for apicectomies. A retrospective study. *Endod Dent Traumatol* 1996;12(4):185-91.
- 4 Locurcio LL, Leeson R. A case of periradicular surgery: apicoectomy and obturation of the apex, a bold act. *Stomatological Dis Sci* 2017;1:76-80.
- 5 Black CV. Amputation of the roots of teeth. In: Litch WF, editor. *The American system of dentistry*. Philadelphia: Lea Brothers; 1886. pp. 990-2.
- 6 Seldin SD. Apicoectomy. *Am J Orthod* 1947;33(4):301-8.
- 7 Nair PN. Cholesterol as an aetiological agent in endodontic failures: a review. *Aust Endod J* 1999;25:19-26.
- 8 Nair PN, Pajarola G, Schroeder HE. Types and incidence of human periapical lesions obtained with extracted teeth. *Oral Surg Oral Med Oral Pathol Oral Radiol Endod* 1996;81:93-102.
- 9 Nair PN, Sjögren U, Krey G, Sundqvist G. Therapy-resistant foreign body giant cell granuloma at the periapex of a root-filled human tooth. *J Endod* 1990;16:589-95.
- 10 Weine FS. *Endodontic therapy*, 6th edition; Mosby Inc. 2004:423-51.
- 11 Qazi SS, Manzoor MA, Khan HH, Arjumand B, Qureshi R. Biphasic resection of a mandibular molar. *J Coll Physicians Surg Pak* 2007;17(5):294-6.
- 12 Nowokowski AT, Serebnitski A, Pesun IJ. Hemisection as a treatment option: A case report. *Oral Health*, 2010 - oralhealthjournal.com.
- 13 Hempton T, Leone C. A review of root resective therapy as a treatment option for maxillary molars. *J Am Dent Assoc* 1997;128(4):449-55.
- 14 von Arx T. Apical surgery: A review of current techniques and outcome. *Saudi Dent J* 2011;23(1):9-15.
- 15 Seymour RA, Meechan JG, Blair GS. Postoperative pain after apicectomy. A clinical investigation. *Int Endod J* 1986;19(5):242-7.
- 16 Molven O, Halse A, Grung B. Observer strategy and the radiographic classification of healing after endodontic surgery. *Int J Oral Maxillofac Surg* 1987;16:432-39.
- 17 Molven O, Halse A, Grung B. Incomplete healing (scar tissue) after periapical surgery radiographic findings 8 to 12 years after treatment. *J Endod* 1996;22:264-68.
- 18 Rud J, Andreasen JO, Jensen JE. Radiographic criteria for the assessment of healing after endodontic surgery. *Int J Oral Surg* 1972;1(4):195-214.
- 19 von Arx T, Jensen SS, Hanni S. Clinical and radiographic assessment of various predictors for healing outcome 1 year after periapical surgery. *J Endod* 2007;33(2):123-8.
- 20 Kim S, Kratchman S. Modern endodontic surgery concepts and practice: a review. *J Endod* 2006;32(7):601-23.
- 21 Song M, Shin SJ, Kim E. Outcomes of endodontic microsurgery: a prospective clinical study. *J Endod* 2011;37(3):316-20.
- 22 Gutmann JL, Gutmann MS. Historical perspectives on the evolution of surgical procedures in endodontics. *J Hist Dent* 2010;58:1-42.
- 23 Tsesis I, Rosen E, Tamse A, Taschieri S, Del Fabbro M. Effect of guided tissue regeneration on the outcome of surgical endodontic treatment: a systematic review and meta-analysis. *J Endod* 2011;37(8):1039-45.
- 24 Taschieri S, Bettach R, Lolato A, Moneghini L, Fabbro MD. Endodontic surgery failure: SEM analysis of root-end filling. *J Oral Sci* 2011;53(3):393-6.
- 25 Leonardi DP, Fagundes FS, Haragushiku GA, Tomazinho PH, Baratto-Filho F. Cirurgiaarendodôntica: valiação de diferentes técnicas para a realização da apicectomia. *RSBO* 2006;3(2):15-9.
- 26 von Arx T, Kurt B. Root-end cavity preparation after apicoectomy using a new type of sonic and diamond-surfaced retrofit: a 1-year follow-up study. *J Oral Maxillofac Surg* 1999;57(6):656-61.
- 27 Tortorici S, Difalco P, Caradonna L, Tetè S. Traditional endodontic surgery versus modern technique: a 5-year controlled clinical trial. *J Craniofac Surg* 2014;25(3):804-7.
- 28 Bernabé PF, Azuma MM, Ferreira LL, Dezan-Júnior E, Gomes-Filho JE, Cintra LT. Root reconstructed with mineral trioxide aggregate and guided tissue regeneration in apical surgery: a 5-year follow-up. *Braz Dent J* 2013;24(4):428-32.
- 29 Jakse N, Ruckenstein M, Rugani P, Kirnbauer B, Sokolowski A, Ebeleseder K. Influence of Extraoral Apicoectomy on Revascularization of an Autotransplanted Tooth: A Case Report. *J Endod* 2018;44(8):1298-302.
- 30 Raedel M, Hartmann A, Bohm S, Walter MH. Three-year outcomes of apicoectomy: mining an insurance database. *J Dent* 2015;43(10):1218-22.

How to cite the article: Avinash S, Agrawal E, Mushtaq I, Bhandari A, Khan F, Thangmawizuali. Apicoectomy: An elucidation to a hitch. *J Dent Specialities* 2019;7(1):28-32.