

Over denture using access post system: an alternative solution for increasing retention

Vankadara SivaKumar¹, R. B. Hallikerimath², Ajinkya Patil³, Megha Sethi⁴

ABSTRACT

^{1,3}Postgraduate,

²Professor and Head of department,
Department of Prosthodontics and Crown
and Bridge, Maratha Mandal's NG Halgekar
Institute Dental Sciences and Research
Centre, Belgaum -590010, Karnataka - India.

⁴Senior Lecturer, I.T.S-Centre for Dental
Studies and Research, Delhi Meerut Road,
Muradnagar, Ghaziabad, Uttar Pradesh –
India.

Corresponding Author:

Dr. Vankadara SivaKumar,
Postgraduate,
Department of Prosthodontics and Crown
and Bridge, Maratha Mandal's NG Halgekar
Institute Dental Sciences and Research
Centre, Belgaum -590010, Karnataka - India.
Email: drvankadara@gmail.com

Received: 28/07/2015

Accepted: 03/09/2015

One of the most common problems encountered by edentulous patients is lack of retention and stability of prosthesis with decreased masticatory efficiency. An overdenture treatment is one of the inevitable solutions for this condition. This case report highlights the use of an "Access post over denture system" which is more advantageous over the conventional tooth supported overdentures. The access post overdenture fabricated was well retentive and esthetic serving as a conservative approach to root preservation.

Keywords: Access post system, Complete denture, Overdenture, Ridge resorption, Stud- attachment.

INTRODUCTION

An overdenture can be described as any removable dental prosthesis that covers and rests on one or more remaining natural teeth, the roots of natural teeth, and/or dental implants.¹ An overdenture offers several advantages over conventional dentures; to name the few are, retaining the residual tooth structure while maintaining its proprioception, preservation of the alveolar bone, and additional support to the dentures apart from the mucosa.² Its acquisitions also include its effectiveness and versatility in restoration and improvisation of facial contour.³ Improvisation in the retention in overdenture can be attained by using various attachment systems which would ultimately contrive in the patient's acceptance.

CASE REPORT

A 64 year old male patient reported to the department of prosthodontics, Maratha Mandal dental College,

Belgaum with the chief complaint of missing teeth, and in ability to chew food. On intra-oral examination, it was found that that upper arch is completely edentulous and partially edentulous lower arch. Teeth found in the lower arch were 33, 43 (Fig. 1). Treatment plan was formulated as a conventional denture in the maxillary arch and an access post retained over denture with access posts in the 33, 43 teeth.

Scaling and root planning followed by intentional root canal treatment of existing teeth no.33 & 43 was done. Teeth no.33 & 43 were reduced in height to a level just 1 mm above the marginal gingiva so as to provide the necessary space for Access ball post. The optimum sizes of the posts were selected by placing them on the undistorted pre-operative IOPA radiographs.

Once the appropriate size of the post was selected post space was prepared in both the mandibular canines using a sequence of Gates Gidden drills followed by the colour coded primary reamer supplied in the Essential Dental Systems Access post overdenture kit which exactly correlates to post size (Fig. 2). Following the radicular preparation in both the mandibular canines the post space was irrigated with saline to remove any debris and then dried up using paper points. The access posts were placed in the post space of both the mandibular canines to check the initial fit and then verified by taking an

Access this article online	
Quick Response Code:	Website: www.its-jds.in
	DOI: 10.5958/2393-9834.2015.00015.7

IOPA radiograph and then, these posts were luted with type-I Glass Inomer cement (Fig. 3).

Routine prosthodontic procedures involved in the fabrication of complete dentures in both upper and lower arches were carried out. These include alginate impressions, border molding, final impressions with addition silicone material followed by facebow transfer and recording of jaw relations, try-in and processing of the dentures (Figs 4,5).

Finally the chair side procedure was carried out to fit the nylon caps in the intaglio surface of the lower denture. The nylon caps with rubber bands were placed on the male part of the posts (Fig. 6). Markings were made on the intaglio surface of the mandibular denture using a disclosing paste and the area was trimmed and sufficiently relieved enough to allow the denture to passively seat over the nylon caps. A small amount of petroleum jelly was applied on the marginal gingiva of the 33 and 43 regions. These nylon caps were picked into the denture directly in the patient's mouth by placing a doughy mixture of self-cure acrylic resin in to the relived space. Patient was instructed to bite in centric occlusion so as to keep it in position until the acrylic is hardened (Fig. 7). Finally the excess amount of acrylic was removed and the denture were finished and polished. The post-operative results can be appreciated in the Fig. 8.

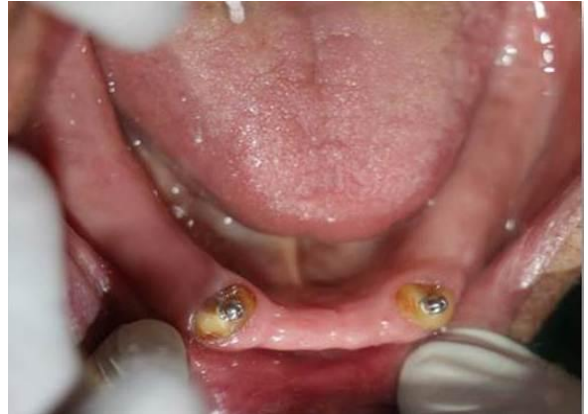

Fig. 3

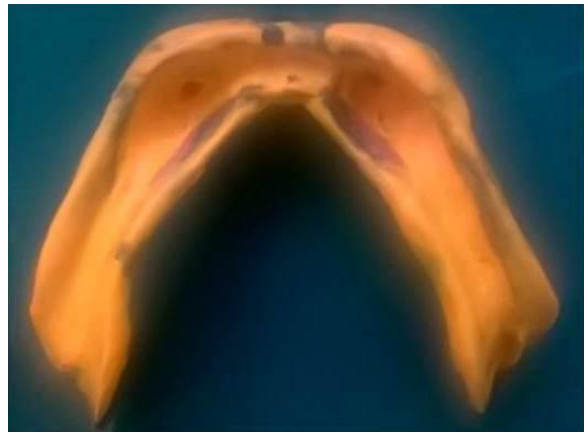

Fig. 4

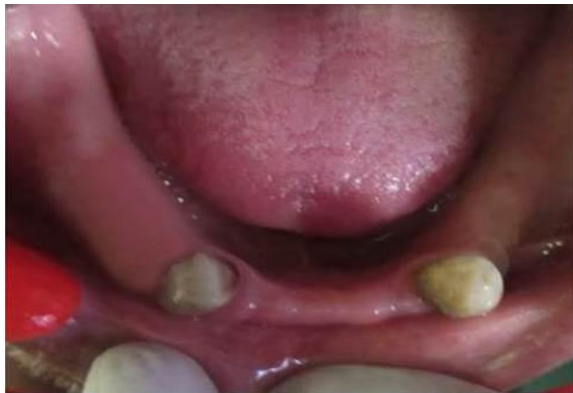

Fig. 1

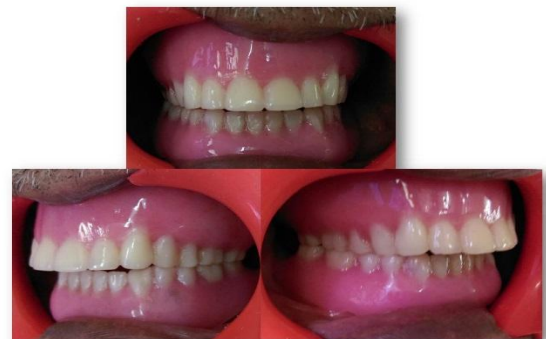

Fig. 5



Fig. 2

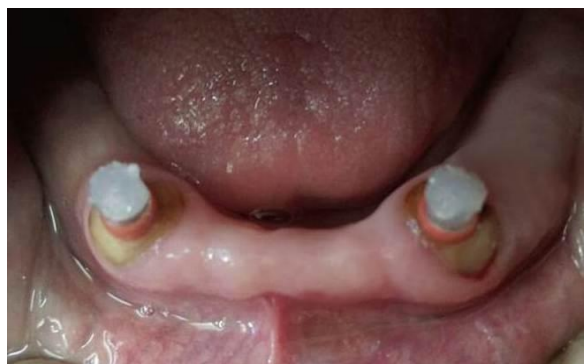

Fig. 6



Fig. 7

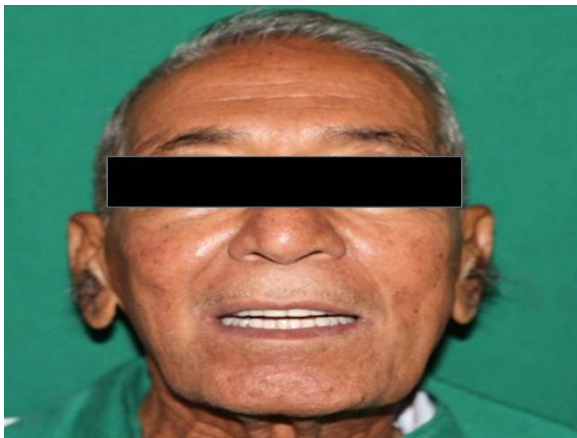


Fig. 8

DISCUSSION

Preventive prosthodontics lays emphasis on any procedure which can delay or eliminate future problems. The basic concept of an overdenture is the preservation of hard and soft tissues in the oral cavity.^{4,5} The phenomenon of residual ridge resorption (RRR) following removal of teeth is well observed and documented in the literature.⁶ It was stated that the bone loss following removal of the teeth is rapid, progressive, irreversible and inevitable. While it was equally observed that it was well maintained around standing teeth and implants.⁷ Bone maintenance is the most significant advantage of a tooth-borne overdenture, because of the maintenance of the bone volume and vertical height which can produce increased prosthetic retention and stability while providing the patient with better comfort and control over mastication due to proprioception.⁸ Over denture attachments have demonstrated a significant positive influence on retention, stability and tissue response.^{9,10} Selection of an attachment is important and it depends upon the available inter-arch space, position of the abutments, and amount of retention required, opposing dentition, clinical experience, personal preference and cost.¹¹ Access post over denture system has a parallel sided passive post with a thick walled hollow tube design. This design provides the strength of a solid shank post and easy retrievability to have an access to the apex of the root in case on a failed root canal. Hollow tube design

allows venting of hydrostatic pressure during cementation. It is basically a stud attachment which occupies a small vertical space and doesn't require parallelism when placed in different roots, and also allows the rotation of the denture. Standard nylon caps provided with this system provides retention of 3-5 pounds and can be easily replaced at a low cost as and when required⁸.

CONCLUSION

In spite of many advances in dental implantology, the conservative approach of root preservation is still valid. Proper case selection and treatment planning is of utmost importance in over denture therapy. However patient maintenance is also important part of overdenture treatment to avoid failures resulting from dental caries and periodontal diseases.

REFERENCES

1. Glossary of Prosthodontic Terms. J Prosthet Dent. 2005;94.
2. DeFranco LR. Overdentures. In, Winkler S (ed), Essential of complete denture prosthodontics, 2nd ed. USA, Inc Publishers, 2004; 384-02.
3. Brewer AA, Morrow RM. Overdentures. 2nd ed. St Louis: CV Mosby; 1980.
4. Winkler .S. Essentials of complete denture Prosthodontics, 2nd ed. 2000:384-02.
5. Kalpana C, Prasad KV. Seeing The Unseen : Preventive Prosthodontics : Use Of Overlay Removable Dental Prosthesis. Annals and Essences of Dent. 2010;2:44-9.
6. Toolson LB, Smith DE. A two year longitudinal study of overdenture patients, Part 1: Incidence and control of caries on overdenture abutments. J Prosthet Dent. 1978;40:486-91.
7. Tallgren A. The continuing reduction of the residual alveolar rides in complete denture wearers: a mixed longitudinal study covering 25 years. J Prosthet Dent. 1972;27:120-32.
8. Jain DC, Hegde V, Aparna I, Dhanasekar B. Overdenture with access post system: A clinical report. Indian J Dent Res. 2011;22:359-62.
9. Burns DR, Unger JW, Elswick RK, Giglio JA. Prospective clinical evaluation of mandibular implant overdentures part II: patient satisfaction and preference. J. Prosth. Dent. 1995;73:364-70.
10. Naert I, Quirynen M, Hooghe M, Van Steenberghe D. A comparative prospective study of splinted and unsplinted Branemark implants in mandibular overdenture therapy: a preliminary report. J Prosth Dent. 1994;71:786-92.
11. Schwartz IS, Morrow RM. Overdentures. Principles and procedures. Dent Clin North Am. 1996;40:169-94.

How to cite this article: SivaKumar V, Hallikerimath RB, Patil A, Sethi M. Over denture using access post system: an alternative solution for increasing retention. J Dent Specialities, 2015;3(2):199-201.

Source of Support: NIL

Conflict of Interest: All authors report no conflict of interest related to this study.